



HAL
open science

Oral-facial-digital syndrome type VI: is C5orf42 really the major gene?

Marta Romani, Francesca Mancini, Alessia Micalizzi, Andrea Poretti, Elide Miccinilli, Patrizia Accorsi, Emanuela Avola, Enrico Bertini, Renato Borgatti, Romina Romaniello, et al.

► To cite this version:

Marta Romani, Francesca Mancini, Alessia Micalizzi, Andrea Poretti, Elide Miccinilli, et al.. Oral-facial-digital syndrome type VI: is C5orf42 really the major gene?. *Human Genetics*, 2015, 134 (1), pp.123-126. 10.1007/s00439-014-1508-3 . hal-01116449

HAL Id: hal-01116449

<https://hal-univ-rennes1.archives-ouvertes.fr/hal-01116449>

Submitted on 17 Jun 2022

HAL is a multi-disciplinary open access archive for the deposit and dissemination of scientific research documents, whether they are published or not. The documents may come from teaching and research institutions in France or abroad, or from public or private research centers.

L'archive ouverte pluridisciplinaire **HAL**, est destinée au dépôt et à la diffusion de documents scientifiques de niveau recherche, publiés ou non, émanant des établissements d'enseignement et de recherche français ou étrangers, des laboratoires publics ou privés.

Oral-facial-digital syndrome type VI: is *C5orf42* really the major gene?

Marta Romani · Francesca Mancini · Alessia Micalizzi · Andrea Poretti · Elide Miccinilli · Patrizia Accorsi · Emanuela Avola · Enrico Bertini · Renato Borgatti · Romina Romaniello · Serdar Ceylaner · Giangennaro Coppola · Stefano D'Arrigo · Lucio Giordano · Andreas R. Janecke · Mario Lituania · Kathrin Ludwig · Loreto Martorell · Tommaso Mazza · Sylvie Odent · Lorenzo Pinelli · Pilar Poo · Margherita Santucci · Sabrina Signorini · Alessandro Simonati · Ronen Spiegel · Franco Stanzial · Maja Steinlin · Brahim Tabarki · Nicole I. Wolf · Federica Zibordi · Eugen Boltshauser · Enza Maria Valente

Received: 30 July 2014 / Accepted: 1 November 2014 / Published online: 19 November 2014
© The Author(s) 2014. This article is published with open access at Springerlink.com

Abstract Oral-facial-digital type VI syndrome (OFDVI) is a rare phenotype of Joubert syndrome (JS). Recently, *C5orf42* was suggested as the major OFDVI gene, being mutated in 9 of 11 families (82 %). We sequenced *C5orf42* in 313 JS probands and identified mutations in 28 (8.9 %), most with a phenotype of pure JS. Only 2 out of 17 OFDVI patients (11.7 %) were mutated. A comparison of mutated vs. non-mutated OFDVI patients showed that preaxial and mesoaxial polydactyly, hypothalamic hamartoma and other congenital defects may predict *C5orf42* mutations, while tongue hamartomas are more common in negative patients.

Electronic supplementary material The online version of this article (doi:10.1007/s00439-014-1508-3) contains supplementary material, which is available to authorized users.

M. Romani · F. Mancini · A. Micalizzi · E. Miccinilli · T. Mazza · E. M. Valente (✉)
Lab. Mendel, IRCCS Casa Sollievo della Sofferenza, Viale Regina Margherita 261, 00198 Rome, Italy
e-mail: e.valente@css-mendel.it

M. Romani
e-mail: m.romani@css-mendel.it

A. Micalizzi
Department of Biological and Environmental Science,
University of Messina, Messina, Italy

A. Poretti
Section of Pediatric Neuroradiology, Division of Pediatric Radiology, The Johns Hopkins School of Medicine,
Baltimore, MD, USA

P. Accorsi · L. Giordano
Pediatric Neuropsychiatric Division, Spedali Civili,
Brescia, Italy

E. Avola
Unit of Pediatrics and Medical Genetics, I.R.C.C.S. Associazione Oasi Maria Santissima, Troina, Italy

Oral-facial-digital type VI syndrome (OFDVI) is a rare phenotype in the spectrum of Joubert syndrome (JS) and is defined by the presence of the “molar tooth sign” (MTS) with at least one of these findings: (1) tongue hamartoma and/or additional lingual frenula and/or upper lip notch; (2) mesoaxial polydactyly; (3) hypothalamic hamartoma. Other oral-facial (e.g. cleft lip and palate) or digital (e.g. postaxial and preaxial polydactyly) abnormalities can also be present (Poretti et al. 2012).

Mutations in *TMEM216* and in *OFDI* have been reported in few OFDVI patients (Coene et al. 2009; Darnency-Stamboul et al. 2013; Valente et al. 2010). A recent study identified mutations in the *C5orf42* gene in nine of 11 OFDVI (82 %) families (including four living children

E. Bertini
Unit of Neuromuscular and Neurodegenerative Disorders,
Laboratory of Molecular Medicine, Bambino Gesù Children's
Research Hospital, Rome, Italy

R. Borgatti · R. Romaniello
Neuropsychiatry and Neurorehabilitation Unit, Scientific
Institute, IRCCS Eugenio Medea, Bosisio Parini, Lecco, Italy

S. Ceylaner
Intergen Genetic Diagnosis, Research and Education Center,
Ankara, Turkey

G. Coppola · E. M. Valente
Section of Neuroscience, Department of Medicine and Surgery,
University of Salerno, Salerno, Italy

S. D'Arrigo
Developmental Neurology Division, Fondazione IRCCS Istituto
Neurologico C. Besta, Milan, Italy

A. R. Janecke
Department of Pediatrics I and Division of Human Genetics,
Innsbruck Medical University, Innsbruck, Austria

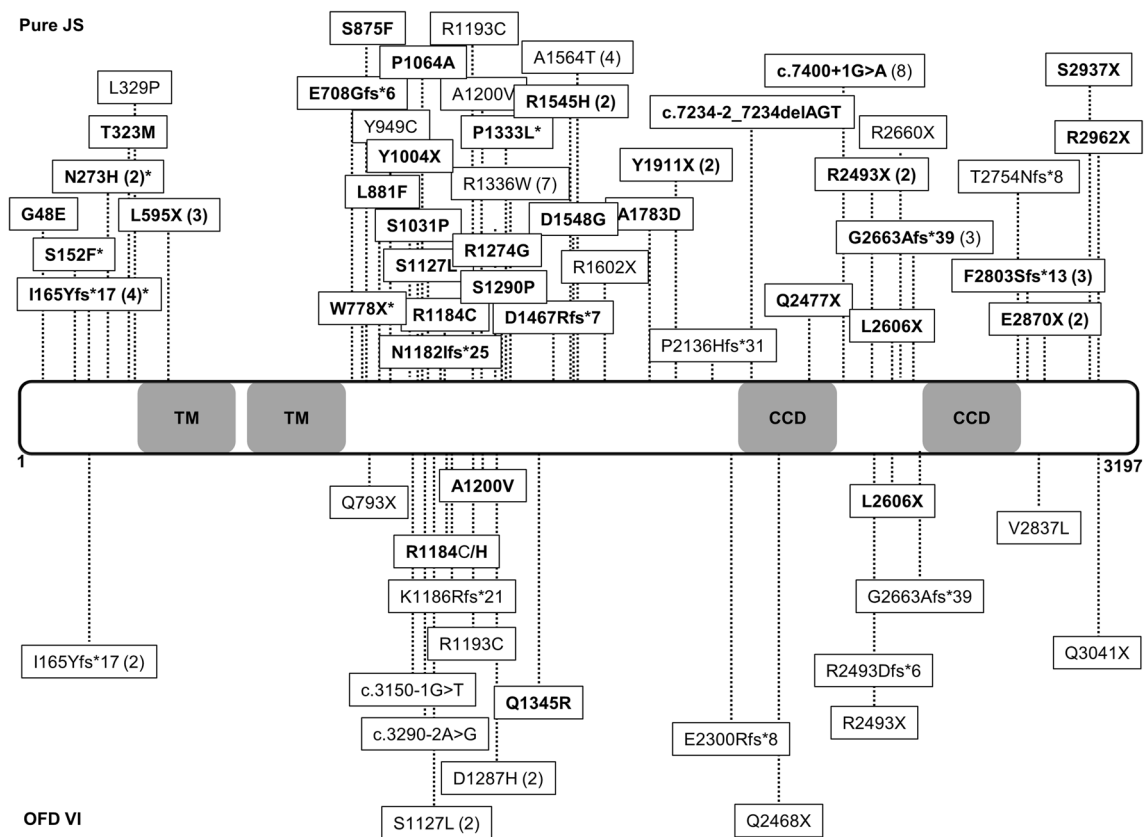


Fig. 1 Schematic representation of C5orf42 protein structure and distribution of all reported mutations. The two predicted transmembrane domains (TM, amino acids 592–612 and 631–651) and the two predicted coiled coil domains (CCD, amino acids 2,457–2,487 and 2,691–2,724) are shown. Mutations found in patients with pure Jou-

bert syndrome and with OFDVI are presented in the *upper* and *lower parts* of the figure, respectively. Mutations identified in the present study are in **bold**. In *brackets* are the numbers of patients in whom each mutation has been identified. *Asterisk* indicates clinical data not available

M. Lituanica

Preconceptional and Prenatal Physiopathology,
Galliera Hospital, Genoa, Italy

K. Ludwig

Surgical Pathology and Cytopathology Unit, Department
of Medicine (DIMED), University of Padova, Padua, Italy

L. Martorell

Department of Molecular Genetics, Hospital
Sant Joan de Déu, Barcelona, Spain

S. Odent

Service de Génétique Médicale, CHU Hôpital Sud,
Rennes, France

L. Pinelli

Department of Neuroradiology, Spedali Civili, Brescia, Italy

P. Poo

Department of Neurology, Hospital Sant Joan de Déu,
Barcelona, Spain

M. Santucci

Pediatric Neuropsychiatry Unit, IRCCS Istituto di Scienze
Neurologiche, Bologna, Italy

S. Signorini

Unit of Child Neurology and Psychiatry, Centre of Child
Neuro-ophthalmology, C. Mondino National Neurological
Institute, Pavia, Italy

A. Simonati

Department of Neurological Sciences and Movement-Neurology
(Child Neurology), University of Verona, Verona, Italy

R. Spiegel

Emek Medical Center, Genetic Institute, Afula, Israel

F. Stanzial

Department of Pediatrics, Genetic Counselling Service,
Regional Hospital of Bolzano, Bolzano, Italy

M. Steinlin

Department of Pediatric Neurology, University Children's
Hospital, Bern, Switzerland

B. Tabarki

Division of Pediatric Neurology, Prince Sultan Military Medical
City, Riyadh, Saudi Arabia

Table 1 Comparison of clinical features in *C5orf42* mutated vs. non-mutated OFDVI patients

	Mutated	Non-mutated	<i>p</i>
Any oral-facial feature	7/12 (58 %)	17/17 (100 %)	0.006
Tongue hamartomas/multiple lingual frenula ^a	6/12 (50 %)	17/17 (100 %)	0.002
Other oral-facial features ^b	4/12 (33 %)	5/17 (29 %)	n.s.
Any polydactyly	14/14 (100 %)	13/17 (76 %)	n.s.
Mesoaxial polydactyly ^a	7/14 (50 %)	1/17 (6 %)	0.01
Preaxial polydactyly	14/14 (100 %)	5/17 (29 %)	0.0001
Postaxial polydactyly	9/14 (64 %)	10/17 (59 %)	n.s.
Any CNS abnormality besides MTS	8/14 (57 %)	4/17 (24 %)	n.s.
Hypothalamic hamartoma ^a	6/14 (43 %)	1/17 (6 %)	0.03
Occipital encephalocele	2/14 (14 %)	1/17 (6 %)	n.s.
Other CNS abnormalities ^c	4/14 (29 %)	2/17 (12 %)	n.s.
Retinal/renal/hepatic involvement	0/14	4/17 (24 %)	n.s.
Retinopathy (only living patients)	0/2	3 ^e /17 (18 %)	n.s.
Nephronophthisis (only living patients)	0/2	2 ^e /17 (12 %)	n.s.
Cystic dysplastic kidneys	0/14	0/17	n.s.
Congenital liver fibrosis	0/14	0/17	n.s.
Other congenital abnormalities outside the CNS ^d	8/14 (57 %)	1/17 (6 %)	0.004

C5orf42 mutated patients include the 12 patients from 9 families reported by Lopez et al. (2014) and the two patients from the present paper; *C5orf42* non-mutated patients ($n = 17$) are all from the present cohort, and include one patient mutated in *OFDI* (see text) and 16 patients from 14 families. Statistical comparisons were made by Fisher's exact test

^a Sufficient for diagnosis of OFDVI in association with the MTS

^b Cleft lip and/or palate, tooth abnormalities, lobulated tongue, short frenula

^c Porencephaly, nodular heterotopia, polymicrogyria, corpus callosum abnormalities, hydrocephalus, arhinencephaly

^d Abnormal ribs or long bones, cubitus valgus, heart or aortic defects, uterus septation, common mesentery, coloboma, microphthalmia, Hirschsprung disease, scoliosis

^e Includes two siblings

and eight fetuses), suggesting that *C5orf42* could represent the major causative gene for OFDVI (Lopez et al. 2014).

As part of a ciliopathy research project, we sequenced *C5orf42* in 313 JS probands, and identified pathogenic mutations in 28 (8.9 %) (Fig. 1). Only two out of 17 OFDVI probands in our cohort (11.7 %) carried *C5orf42* mutations, while one was mutated in *OFDI*. No mutations were detected in the remaining 14 (82.3 %) OFDVI patients

N. I. Wolf

Department of Child Neurology, VU University Medical Center and Neuroscience Campus Amsterdam, Amsterdam, The Netherlands

F. Zibordi

Department of Child Neurology, Fondazione IRCCS Istituto Neurologico "Carlo Besta", Milan, Italy

E. Boltshauser

Department of Pediatric Neurology, University Children's Hospital, Zurich, Switzerland

E. M. Valente

Neurogenetics Unit, CSS-Mendel Institute, Viale Regina Margherita 261, 00198 Rome, Italy

in all tested genes (see Supplementary material online for methods, characterization of mutations and clinical features of mutated OFDVI patients).

To explain the striking discrepancy between our findings and those reported by Lopez et al., we compared clinical features in *C5orf42* mutated ($n = 14$) vs. non-mutated ($n = 17$) OFDVI patients (Table 1). Preaxial and mesoaxial polydactyly, hypothalamic hamartomas and other congenital abnormalities were significantly more frequent in the mutated group, while tongue hamartomas or multiple lingual frenula occurred more commonly in non-mutated patients. Other oral-facial features, postaxial polydactyly and other brain abnormalities were equally represented in both groups. Despite the limited number of patients, these findings suggest that the current diagnostic criteria for OFDVI include two main phenotypic groups, one with preaxial and/or mesoaxial polydactyly and frequent additional congenital anomalies (for which *C5orf42* is the major causative gene), and another with less severe presentation and prevalent oral-facial involvement, which genetic causes still remain to be identified.

Twenty-seven *C5orf42* mutated patients (from 23 families) in our study had pure JS (with retinopathy in one),

while clinical data were unavailable in three. Considering all reported *C5orf42* mutated patients ($n = 58$), over two-thirds showed a pure JS phenotype while only 24 % has OFDVI (Supplementary Table 1). Kidney or liver involvement was never noted, while polydactyly (mainly preaxial) was present in nearly half of mutated patients regardless of the phenotype. These findings delineate a specific *C5orf42*-related phenotype, and suggest a major role for this gene in limb development.

Overall, the identification of mutations in 28 of 313 JS probands makes *C5orf42* a major contributor to the pathogenesis of this ciliopathy. How mutations in the same gene may cause pure JS or a much more severe oral-facial-digital syndrome remains an open question. Genotype–phenotype correlations seem to fail, since truncating and missense mutations affecting the entire length of the protein are detected in patients with either pure or OFDVI presentations (Fig. 1). As suggested for other ciliopathies, it is conceivable that additional, yet unidentified variants in distinct genes may act as genetic modifiers able to influence the penetrance and expression of oral-facial and digital features in patients bearing *C5orf42* mutations.

Acknowledgments This work was partly supported by grants from the European Research Council (ERC Starting Grant 260888), the Telethon Foundation Italy (Grant GGP13146), and the Italian Ministry of Health (Ricerca Corrente 2014, Ricerca Finalizzata Malattie Rare 2008).

Open Access This article is distributed under the terms of the Creative Commons Attribution License which permits any use, distribution, and reproduction in any medium, provided the original author(s) and the source are credited.

References

Coene KL, Roepman R, Doherty D, Afroze B, Kroes HY, Lettboer SJ, Ngu LH, Budny B, van Wijk E, Gorden NT, Azhimi M, Thauvin-Robinet C, Veltman JA, Boink M, Kleefstra T,

Cremers FP, van Bokhoven H, de Brouwer AP (2009) OFD1 is mutated in X-linked Joubert syndrome and interacts with LCA5-encoded lebercilin. *Am J Hum Genet* 85:465–481. doi:10.1016/j.ajhg.2009.09.002

Darmency-Stamboul V, Burglen L, Lopez E, Mejean N, Dean J, Franco B, Rodriguez D, Lacombe D, Desguerres I, Cormier-Daire V, Doray B, Pasquier L, Gonzales M, Pastore M, Crenshaw ML, Huet F, Gigot N, Aral B, Callier P, Faivre L, Attie-Bitach T, Thauvin-Robinet C (2013) Detailed clinical, genetic and neuroimaging characterization of OFD VI syndrome. *Eur J Med Genet* 56:301–308. doi:10.1016/j.ejmg.2013.03.004

Lopez E, Thauvin-Robinet C, Reversade B, Khartoufi NE, Devisme L, Holder M, Ansart-Franquet H, Avila M, Lacombe D, Kleinfinger P, Kaori I, Takahashi JI, Le Merrer M, Martinovic J, Noel C, Shboul M, Ho L, Guven Y, Razavi F, Burglen L, Gigot N, Darmency-Stamboul V, Thevenon J, Aral B, Kayserili H, Huet F, Lyonnet S, Le Caignec C, Franco B, Riviere JB, Faivre L, Attie-Bitach T (2014) *C5orf42* is the major gene responsible for OFD syndrome type VI. *Hum Genet* 133:367–377. doi:10.1007/s00439-013-1385-1

Poretti A, Vitiello G, Hennekam RC, Arrigoni F, Bertini E, Borgatti R, Brancati F, D'Arrigo S, Faravelli F, Giordano L, Huisman TA, Iannicelli M, Kluger G, Kyllerman M, Landgren M, Lees MM, Pinelli L, Romaniello R, Scheer I, Schwarz CE, Spiegel R, Tibussek D, Valente EM, Boltshauser E (2012) Delineation and diagnostic criteria of Oral-Facial-Digital Syndrome type VI. *Orphanet J Rare Dis* 7:4. doi:10.1186/1750-1172-7-4

Valente EM, Logan CV, Mougou-Zerelli S, Lee JH, Silhavy JL, Brancati F, Iannicelli M, Travaglini L, Romani S, Illi B, Adams M, Szymanska K, Mazzotta A, Lee JE, Tolentino JC, Swistun D, Sali-pietro CD, Fede C, Gabriel S, Russ C, Cibulskis K, Sougnez C, Hildebrandt F, Otto EA, Held S, Diplas BH, Davis EE, Mikula M, Strom CM, Ben-Zeev B, Lev D, Sagie TL, Michelson M, Yaron Y, Krause A, Boltshauser E, Elkhartoufi N, Roume J, Shalev S, Munnich A, Saunier S, Inglehearn C, Saad A, Alkindy A, Thomas S, Vekemans M, Dallapiccola B, Katsanis N, Johnson CA, Attie-Bitach T, Gleeson JG (2010) Mutations in *TMEM216* perturb ciliogenesis and cause Joubert, Meckel and related syndromes. *Nat Genet* 42:619–625. doi:10.1038/ng.594