HAL
open science

Unusual presentation of neuralgic amyotrophy with impairment of cranial nerve XII

Margaux Genevray, Mathieu Kuchenbuch, Anne Kerbrat, Paul Sauleau

To cite this version:

Margaux Genevray, Mathieu Kuchenbuch, Anne Kerbrat, Paul Sauleau. Unusual presentation of neuralgic amyotrophy with impairment of cranial nerve XII. Muscle & nerve. Supplement., 2016, 54 (2), pp.335-336. 10.1002/mus.25031 . hal-01263108

HAL Id: hal-01263108

https://univ-rennes.hal.science/hal-01263108

Submitted on 22 Apr 2016

HAL is a multi-disciplinary open access archive for the deposit and dissemination of scientific research documents, whether they are published or not. The documents may come from teaching and research institutions in France or abroad, or from public or private research centers.

L'archive ouverte pluridisciplinaire **HAL**, est destinée au dépôt et à la diffusion de documents scientifiques de niveau recherche, publiés ou non, émanant des établissements d'enseignement et de recherche français ou étrangers, des laboratoires publics ou privés.

Unusual presentation of neuralgic amyotrophy with impairment of cranial nerve XII

Margaux Genevray MD[1], Mathieu Kuchenbuch MD[1], Anne Kerbrat MD[2], Paul Sauleau MD, PhD [3]

[1] Department of Neurophysiology, Rennes University Hospital, Rennes, France

[2] Department of Neurology, Rennes University Hospital, Rennes, France

[3] "Behavior and Basal Ganglia" research unit (EA 4712), University of Rennes, Rennes, France

Corresponding author:

Paul Sauleau, MD, PhD

EA 4712 "Comportement et Noyaux Gris Centraux", Université de Rennes 1, Faculté de Médecine, Avenue Léon Bernard, Rennes 35043, France

Tel.: +33 (0) 299 289 842; Fax: +33 (0) 299 284 132; e-mail: paul.sauleau@univ-rennes1.fr

Running title: Neuralgic amyotrophy with hypoglossal neuropathy

Keywords: brachial plexus neuropathy; neuralgic amyotrophy; Parsonage–Turner syndrome; cranial nerve XII; hypoglossal nerve

Word count: Main text: 497 (excluding legends and references). 8 references, 1 figure

Conflicts of interest: The authors declare that they have no conflicts of interest concerning this article.

Study funding: No targeted funding reported.

Acknowledgments: Special thanks to Elizabeth Portier for reviewing the English style.

Accepted Article

Accepted Article

We describe a patient with typical features of neuralgic amyotrophy (NA) [1, 2], who also had an isolated hypoglossal neuropathy.

Case report.

A 46-year-old man was admitted for sudden deviation of the tongue which affected articulation of lingual sounds (Figure, A). He had experienced a flu-like syndrome 8 days before the occurrence of severe pain in the right shoulder with less severe pain in the region of the left scapula. Tongue weakness began 24 hours later, and the pain decreased rapidly. Examination was normal except for right tongue deviation (Figure, A), weakness of flexion of the interphalangeal joint of the right thumb (Figure, B), and right scapular winging (Figure, C). Brain and brachial plexus MRI, blood tests, lumbar puncture, and stool studies (Lyme disease, vasculitis, and viral infection) were normal. Conduction studies of the median, ulnar, and lateral antebrachial cutaneous nerves, performed 11 days after onset of symptoms, were normal and bilaterally symmetrical. Electromyographic recordings revealed reduced recruitment of motor unit potentials, which was moderate in the right biceps brachii and marked in the tongue, flexor pollicis longus, serratus anterior, and supraspinatus muscles. There was no abnormal spontaneous activity in these muscles. Corticosteroids were administered for 10 days. Follow-up electromyography 1 month later yielded similar findings, plus fibrillation potentials and positive sharp waves in the right serratus anterior and decreased right median sensory nerve action potentials in the first (16 vs. 26μV on the left side) and second (17μV vs. 31μV) digits. Eight months later, the patient had only slight tongue deviation and a mild deficit in right thumb flexion. The scapular winging persisted, and there was marked atrophy of the serratus anterior and supraspinatus muscles.

Discussion

This report illustrates the unusual development of hypoglossal neuropathy in the setting of otherwise typical NA with multiple shoulder girdle neuropathies. In its common

Accepted Article

form, NA involves the brachial plexus, with frequent impairment of the suprascapular, anterior interosseous, or long thoracic nerves [1]. NA may also involve the cranial nerves (CNs) [3–7], though more frequently in its hereditary form [1]. Despite the lack of familial disease, hereditary NA cannot be ruled out in our patient, as we did not perform genetic testing. In the series studied by Van Alfen and colleagues, only 17.3% of patients with idiopathic NA had impairment outside the brachial plexus, either in the lumbosacral plexus (8.2%), phrenic nerve (6.6%), or recurrent laryngeal nerve (2%) [1]. In hereditary NA, impairment outside the brachial plexus occurred in up to 55.8% of patients, with involvement of the recurrent laryngeal nerve reported in 18.6% [1]. Involvement of the CNs may either be isolated or associated with plexopathy, and the onset of symptoms can occur in either the CN(s) or the upper limb(s) [3–8]. Usually, several CNs are affected simultaneously, with impairment of a combination of nerves IX, X, XI, and XII [4, 5] or bilateral VII [3]. Impairment of a single CN has only been reported for the recurrent laryngeal nerve [6] or CN XI [3].

List of acronyms or abbreviations used in the manuscript

CN(s): cranial nerve(s)

NA: neuralgic amyotrophy

Accepted Article

References

1 Van Alfen N, van Engelen BGM. The clinical spectrum of neuralgic amyotrophy in 246 cases. *Brain J Neurol* 2006;**129**:438–450.

2 Van Alfen N. Clinical and pathophysiological concepts of neuralgic amyotrophy. *Nat Rev Neurol* 2011;**7**:315–322.

3 Cruz-Martínez A, Barrio M, Arpa J. Neuralgic amyotrophy: variable expression in 40 patients. *J Peripher Nerv Syst* 2002; **7**:198–204.

4 Pierre PA, Laterre CE, Van den Bergh PY. Neuralgic amyotrophy with involvement of cranial nerves IX, X, XI and XII. *Muscle Nerve* 1990;**13**:704–707.

5 Zuberbuhler P, León Cejas LV, Binaghi D, Reisin RC. Acute brachial plexus neuropathy with involvement of cranial nerves IX, X, XI and XII. *J Neurol Sci* 2013;**334**:169–171.

6 Samarà L, Valls-Sole J, Caballero M. Dysphonia as an unusual debut of Parsonage-Turner syndrome. *Head Neck* 2013;**35**:E229–E230.

7 Pinto MV, Joffily L, Vincent MB. Recurrent vocal fold paralysis and parsonage-turner syndrome. *Case Rep Otolaryngol* 2013, 763201.

8 Holtbernd F, Zehnhoff-Dinnesen AA, Duning T, Kemmling A, Ringelstein EB. An unusual case of neuralgic amyotrophy presenting with bilateral phrenic nerve and vocal cord paresis. *Case Rep Neurol* 2011;**3**:69–74.

Legend for the figure

Photos of the patient: (A) tongue deviation, (B) a moderate motor deficit in the flexion of the last phalanx of the right thumb due to impairment of the anterior interosseous nerve innervating the flexor pollicis longus muscle, and (C) right scapular winging due to impairment of the long thoracic nerve innervating the serratus anterior muscle.

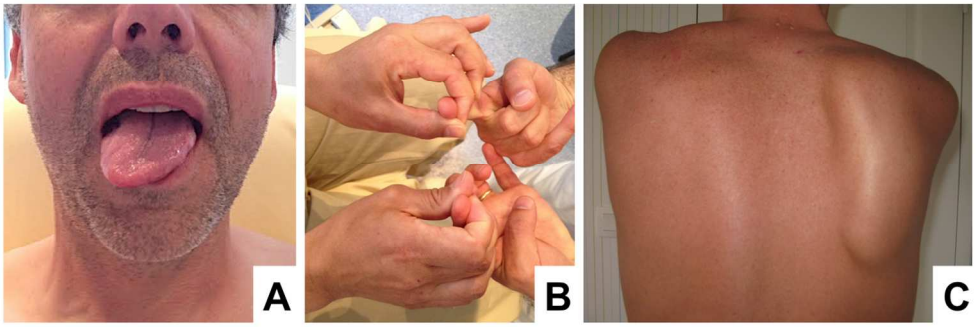

127x42mm (300 x 300 DPI)

Accepted A