

VIRTUAL IMPLANTATION OF A NOVEL LVAD: TOWARDS COMPUTER-ASSISTED SURGERY FOR HEART FAILURE

Short title: Virtual implantation of LVADs

Amedeo ANSELMI*[§], MD PhDs, Sophie COLLIN[§], Pascal HAIGRON[§],
PhD, Jean-Philippe VERHOYE*[§], MD PhD, Erwan FLECHER*[§], MD
PhD

*Division of Thoracic and Cardiovascular Surgery, Pontchaillou University Hospital,
Rennes, France

[§]INSERM (French National Institute for Healthcare and Medical Research) Unit 1099

[°]LTSI (*Laboratoire de Traitement du Signal et de l'Image*), University of Rennes 1,
Rennes, France

Address for correspondence:

Amedeo Anselmi, MD PhDs
Division of Thoracic and Cardiovascular Surgery
Pontchaillou University Hospital
2, rue Henri le Guilloux, 35000 Rennes, France
Tel# 0033(0)637060379
Fax# 0033(0)299282497
Email: amedeo.anselmi@alice.it

TEXT WORD COUNT: 1,130

ABSTRACT WORD COUNT: 189

Sources of Funding: 'Association Ouest Transplant' (Western French Transplantation Association) (partial financial support).

Abstract

Background. Mechanical and hemodynamic factors are among the determinants of patient-device interaction and early- and long-term outcomes in left ventricular assist device (LVAD) recipients.

Material and Methods. We are currently developing computer simulation tools aimed at: 1. analyze the intrathoracic and intracavitary positioning of LVADs after implantation and establish correlation with clinical outcomes; 2. assist surgeons in the choice of device and of left ventricular coring site for optimized intrathoracic placement and function; 3. facilitate the planning of less invasive LVAD implantation. A virtual representation of LVAD (mesh device component) was created through cone-beam computed tomography and semiautomatic segmentation. A modular framework software (CamiTK, Grenoble, France) was employed to create a three-dimensional representation of patients' CT-scan and incorporate the mesh device component for virtual implantation.

Results. Device reconstruction was included into a dedicated software with the purposes of virtual implantation, based on the preoperative CT scan of surgical candidates.

Conclusions. We present herein the first digital reconstruction of the novel HeartMate 3 LVAD. Virtual implantation on the basis of preoperative CT scan is feasible within a user-friendly interactive software. Future studies will be focused on correlation with clinical variables.

Authors' contribution.

Conception and design: AA, SC, EF

Writing the paper: AA, SC

Critical revision of the paper: PH, JPV, EF

KEY WORDS: Left Ventricular Assist Device; Computer-assisted surgery; Preoperative simulation

Introduction.

Despite its effectiveness in improving survival and quality-of-life in patients with advanced heart failure [1], Left Ventricular Assist Device (LVAD) treatment is still associated with severe complications such as thromboembolic events, pump thrombosis and pump dysfunction. Mechanical and hemodynamic factors related to suboptimal pump implantation and positioning have been associated with an increased likelihood of developing adverse events [2, 3, 4]. Our ultimate research purpose is to develop innovative tools to assist surgeons in the choice of devices, of optimal site of left ventricular wall coring and in intrathoracic pump positioning, with the scope to optimize pump function, avoid secondary migration after chest closure, and minimize thromboembolic risk due to mechanical and hemodynamic factors in a patient-specific fashion. We assembled a team consisting of heart failure surgeons (AA and EF), biomedical engineers (SC) and an expert in biomedical image processing for innovative clinical applications (PH). The preliminary results of this project have included the development of a computer interface allowing spatial manipulation and virtual implantation of LVADs within a three-dimensional representation of patients' CT scan, and an analysis tool for intraventricular cannula positioning in implanted patients presenting LVAD-related complications at follow-up (Figure 1).

The HeartMate 3 (Thoratec Inc., Pleasanton, CA) is a novel rotary magnetically-driven LVAD which has recently obtained the CE mark and is entering the clinical practice. We present the inclusion of this device within a virtual implantation tool (which is currently for investigational and pre-clinical use only). We highlight the

features of the device and the potential for computer-assisted surgery in the domain of heart failure.

Methods and Results.

The HeartMate 3 device was represented by a three-dimensional digital object (mesh component) later included in the virtual implantation software. To this purpose, a rotational imaging of the device was performed (Cone-Beam Computed Tomography – CBCT) using an Artis Zeego fluoroscopy equipment (Siemens Healthcare Inc., Munich, Germany) in order to minimize artifacts (Video 1). The ITK-Snap software (Philadelphia, PA) was used to perform semiautomatic segmentation of the acquired images and obtain the three-dimensional mesh component representation (Figure 2). This reliably depicted the volumes of the device, including the inflow cannula, the apical sewing ring, the pump body and the outflow tract (Video 1). The Dacron portion of the outflow was not reconstructed given its adaptability to native anatomy. The HeartMate 3 LVAD has a more compact size than the HeartMate II device in order to improve ease of implantation, although the site of left ventricular coring and the orientation of the apical cannula still represent important features in the determinism of pump function. For the performance of virtual implantation, the mesh device component is incorporated into a three-dimensional representation of the patient's CT scan within a modular framework software (CamiTK - Computer Assisted Medical Intervention Toolkit, Grenoble, France). Through such software, the user can visualize and browse the coronal, sagittal and transverse views of the CT-scan; a three-dimensional representation of

the cardiac chambers is also obtained through a multi-atlas based methodology and a per-voxel majority voting procedure, as previously described [4 5] (Video 2). This three-dimensional representation of cardiac chambers is superimposed to CT-scan images (augmented visualization of CT-scan). Coaxiality with the mitral valve orifice and non-conflict with the interventricular septum and left ventricular cavity walls are considered as requirements for correct placement of LVAD inflow cannula. Hence, the user elaborates the CT scan through dedicated widgets in order to identify the mitral valvular orifice. Subsequently, the software suggests the LVAD implantation site and left ventricular coring location which maximize mitral valve coaxiality in the individual patient (Video 2). The software subsequently shows the overlap between the virtually implanted LVAD and the osseous chest wall, in order to help the surgeon estimate the risk of conflict and device migration from the intended position after chest closure.

Discussion.

Computer-assisted surgery is a complex discipline integrating different technologies and data sources, such as pre- and intraoperative imaging, interactive simulation, virtual or augmented reality, and micro-technologies [6, 7]. It has contributed to significant advancements in orthopedics and neurosurgery [8], but also in aortic surgery [8] and transcatheter valve implantation. Our investigational purpose is to introduce this discipline into the field of heart failure surgery, in order to optimize LVAD implantation in a patient-specific fashion and potentially minimize the rate of early and late LVAD-related complications. The general principles of LVAD

implantation are well-known [2]. Nonetheless, patient-dependent variability in left ventricular dimension and morphology depending on the underlying disease, as well as variability in the conformation of the thoracic cavity, may influence not only the risk of device migration/malposition after chest closure, but also intraventricular cannula displacement with potential for suboptimal drainage or thrombus formation. Several Authors have previously attempted developments in such perspective [10, 11]. With the present project, we sought for the first time to develop a user-friendly tool for the planning the implantation of a LVAD. This will ultimately take into consideration the intrathoracic placement with respect to the rigid chest wall, the identification of optimal sites for both apical coring and ascending aortic outflow, including performance of intracavitary fluidic simulations.

The intended preoperative planning tool will allow virtual implantation of several commercially available LVADs. The new HeartMate 3 device presents a more compact size than its predecessor HeartMate II. Such feature could facilitate intrathoracic positioning in patients with smaller body surface area or with chest wall deformities. Similarly, preoperative virtual implantation will be expectedly employed also in the planning of less invasive LVAD implantation through minithoracotomy. The present research is expected in perspective to facilitate patient-specific preoperative simulation of optimal left ventricular coring site and LVAD implantation with the aid of computer-assisted surgery techniques. The final intraventricular orientation of the inflow cannula taking into account both the coring site and the mechanical effects of the thoracic wall could be anticipated. Although further investigations are needed to such point, we have data about the association between suboptimal inflow cannula alignment (namely towards the interventricular septum) and complications at follow-up (stroke, thromboembolic events). Such findings were obtained through elaboration

of postoperative CT-scan images from LVAD recipients as previously described, and have been recently published [12]. It has been proposed that device migration over time is limited and has scarce effect on the incidence of late complications [13]. While the conflict between the device and the chest wall can be easily analyzed digitally [12], the anticipation of left ventricular remodeling and volume reduction after initiation of LVAD support is a more complex problem requiring dedicated developments.

In conclusion, herein we present the first digital reconstruction of the novel HeartMate 3 device, for intended integration within a LVAD preoperative simulation tool which is currently under development. Virtual implantation of the HeartMate 3 can be performed in an easy and rapid fashion. Interpretation of results and correlation with clinical variables are currently under evaluation.

Acknowledgements

Sources of Funding: ‘*Association Ouest Transplant*’ (Western French Transplantation Association) (partial financial support).

The Authors are grateful to Thoratec Inc. for the kind support in material for the performance of the present study.

This work has been partially conducted in the experimental platform TherA-Image (Rennes, France) supported by Europe FEDER.

Conflicts of interest

None.

References

1. Rose EA, Gelijns AC, Moskowitz AJ, Heitjan DF, Stevenson LW, Dembitsky W et al. Long-term use of a left ventricular assist device for end-stage heart failure. *N Engl J Med.* 2001;345:1435-43.
2. Adamson RM, Mangi AA, Kormos RL, Farrar DJ, Dembitsky WP. Principles of HeartMate II implantation to avoid pump malposition and migration. *J Card Surg.* 2015;30:296-9.
3. Taghavi S, Ward C, Jayarajan SN, Gaughan J, Wilson LM, Mangi AA. Surgical technique influences HeartMate II left ventricular assist device thrombosis. *Ann Thorac Surg.* 2013;96:1259-65.
4. Ward C, Wilson L, Dries D, Mangi A. Surgical Technique Influences Heartmate-2 Left Ventricular Assist Device Thrombosis. *J Surg Res* 2013;179:185.
5. Kirişli HA, Schaap M, Klein S, Papadopoulou SL, Bonardi M, Chen CH et al. Evaluation of a multi-atlas based method for segmentation of cardiac CTA data: a large-scale, multicenter, and multivendor study. *Med Phys.* 2010;37:6279-91.
6. Haignon P, Dillenseger JL, Luo L, Coatrieux JL. Image-guided therapy: evolution and breakthrough. *IEEE Eng Med Biol Mag.* 2010;29:100-4.
7. Peters TM. Image-guidance for surgical procedures. *Phys Med Biol.* 2006;51:R505-40.
8. Wang LL, Leach JL, Breneman JC, McPherson CM, Gaskill-ShIPLEY MF. Critical role of imaging in the neurosurgical and radiotherapeutic management of brain tumors. *Radiographics.* 2014;34:702-21.

9. Kaladji A, Lucas A, Kervio G, Haigron P, Cardon A. Sizing for endovascular aneurysm repair: clinical evaluation of a new automated three-dimensional software. *Ann Vasc Surg.* 2010;24:912-20.
10. Ong C, Dokos S, Chan B, Lim E, Al Abed A, Bin Abu Osman NA et al. Numerical investigation of the effect of cannula placement on thrombosis. *Theor Biol Med Model.* 2013;10:35.
11. Karmonik C, Partovi S, Loebe M, Schmack B, Weymann A, Lumsden AB et al. Computational fluid dynamics in patients with continuous-flow left ventricular assist device support show hemodynamic alterations in the ascending aorta. *J Thorac Cardiovasc Surg.* 2014;147:1326-1333.e1.
12. Anselmi A, Collin S, Haigron P, Verhoye JP, Flecher E. Virtual implantation and patient-specific simulation for optimization of outcomes in ventricular assist device recipients. *Med Hypotheses.* 2016;91:67-72.
13. Truong TV, Stanfield JR, Chaffin JS, Elkins CC, Kanaly PJ, Horstmanshof DA et al. Postimplant left ventricular assist device fit analysis using three-dimensional reconstruction. *ASAIO J.* 2013;59:586-92.

Figure Legends

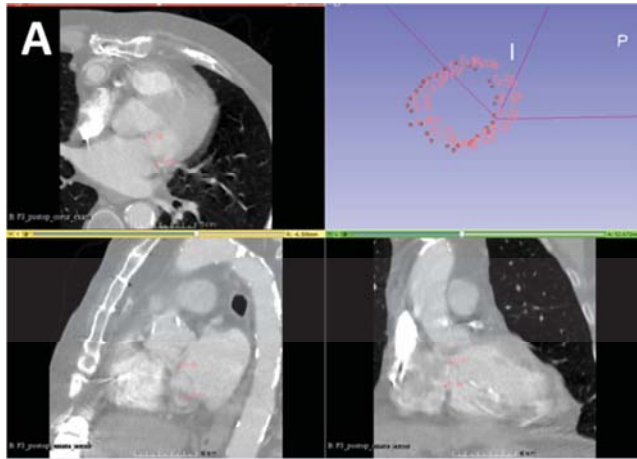
Figure 1. **A.** Screenshot of a LVAD implantation preoperative planning and postoperative analysis tool: definition of the mitral annulus by the user on post-implantation CT scan. **B.** Three-dimensional representation of the cardiac chambers after segmentation with the obtained mitral orifice plane. **C.** Coordinates system for the LVAD apical cannula orientation with respect to the mitral valvular orifice; description through angles θ and φ for quantification of displacement from ideal orientation. IVS: Interventricular Septum.

Figure 2. Process of creation of a LVAD mesh component (CBCT, segmentation and three-dimensional mesh).

Video Legends

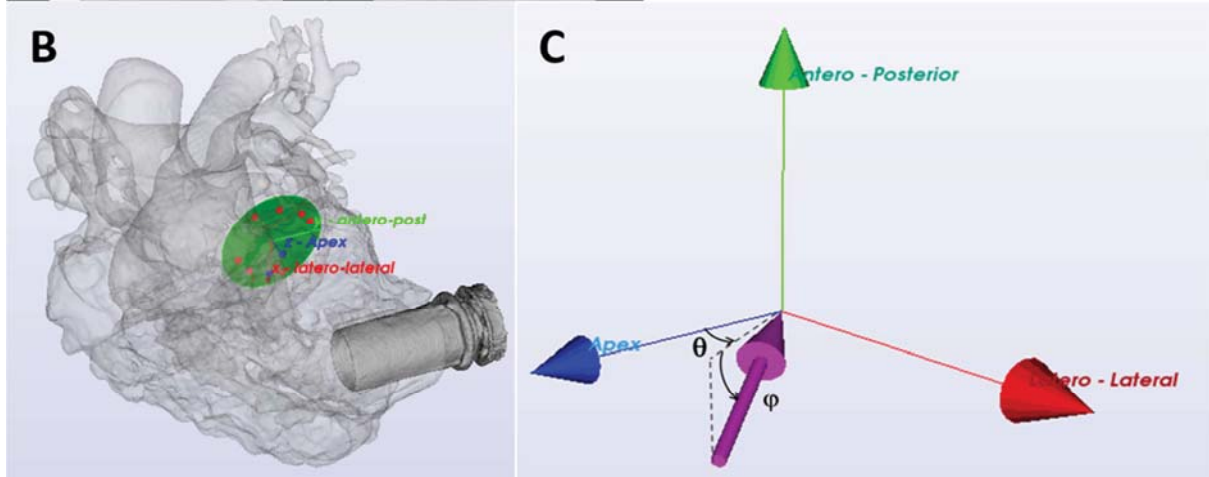
Video 1. CBCT of a HeartMate 3 LVAD and final three-dimensional mesh component representation.

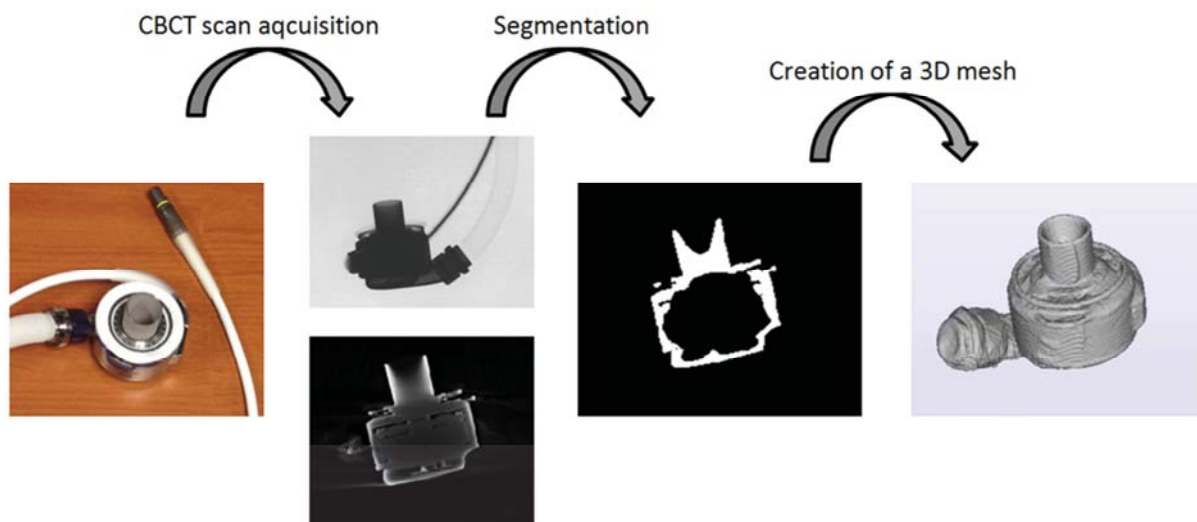
Video 2. Virtual implantation of a HeartMate 3 LVAD. The segmentation of cardiac structures (multi-atlas methodology) is integrated within a three-dimensional visualization of patient's preoperative CT scan. The LVAD mesh component is integrated and virtually implanted at the epicardial region which allows best alignment with the mitral valvular orifice (as previously defined by the user). The CT scan can be subsequently scrolled with the device in place. LV: Left Ventricular. LA: Left Atrial.



$$\theta = -41.17 \text{ (45.7\% inferior)}$$
$$\varphi = -82.54 \text{ (91.7\% towards IVS)}$$

Orientation analysis of the LVAD apical cannula – Correlation with clinical data and adverse events at follow-up





ACCEPTED MANUSCRIPT