



HAL
open science

Performance of noninvasive laser Doppler flowmetry and laser speckle contrast imaging methods in diagnosis of Buerger disease. A case report

Loukman Omarjee, Antoine Larralde, Vincent Jaquinandi, Olivier Stivalet, Guillaume Mahé

► To cite this version:

Loukman Omarjee, Antoine Larralde, Vincent Jaquinandi, Olivier Stivalet, Guillaume Mahé. Performance of noninvasive laser Doppler flowmetry and laser speckle contrast imaging methods in diagnosis of Buerger disease. A case report. *Medicine*, 2018, 97 (43), pp.e12979. 10.1097/MD.00000000000012979 . hal-01936323

HAL Id: hal-01936323

<https://hal-univ-rennes1.archives-ouvertes.fr/hal-01936323>

Submitted on 17 Jul 2019

HAL is a multi-disciplinary open access archive for the deposit and dissemination of scientific research documents, whether they are published or not. The documents may come from teaching and research institutions in France or abroad, or from public or private research centers.

L'archive ouverte pluridisciplinaire **HAL**, est destinée au dépôt et à la diffusion de documents scientifiques de niveau recherche, publiés ou non, émanant des établissements d'enseignement et de recherche français ou étrangers, des laboratoires publics ou privés.

Performance of noninvasive laser Doppler flowmetry and laser speckle contrast imaging methods in diagnosis of Buerger disease

A case report

Loukman Omarjee, MD, MSc^{a,b,c,*}, Antoine Larralde, MD, MSc^d, Vincent Jaquinandi, MD, PhD^{a,b}, Olivier Stivalet, MD^{a,b}, Guillaume Mahe, MD, PhD^{a,b}

Abstract

Rationale: Buerger disease (BD) is a nonatherosclerotic, inflammatory, segmental vascular occlusive disease, which affects small and medium-sized arteries and veins and is triggered by substantial tobacco exposure. Angiographic findings consistent with BD are required for diagnosis. Laser Doppler flowmetry (LDF) and laser speckle contrast imaging (LSCI) could represent potential noninvasive alternative techniques to angiography.

Patient concerns: We report the case of a 49-year-old smoker who developed an ischemic ulcer in the distal segment of the second finger of the left hand. He had no medical history.

Diagnoses: In our vascular center, LDF and LSCI are conducted routinely for digital artery disease diagnosis. LDF was indicative of digital obstructive artery disease (DOAD). Postocclusive reactive hyperemia, assessed by LSCI, demonstrated no skin blood flow (SBF) perfusion in the distal phalanx of the thumb, index, middle, and auricular fingers. Angiography confirmed BD, showing distally located multisegmental vessel occlusion and corkscrew collaterals in this patient's hands.

Interventions: Ilomedine treatment was initiated and smoking cessation was definitive.

Outcomes: Recently, the patient had an improvement in clinical condition despite the persistence of a small zone of necrosis of the left index finger 28 days post-treatment.

Lessons: Our observation suggests that where suspicion of BD is based on clinical criteria, combining LDF and LSCI could represent a noninvasive, safe means of reaching BD diagnosis. Further clinical trials are necessary to confirm this novel observation.

Abbreviations: a.u. = arbitrary units, BD = Buerger disease, CTA = computed tomography angiography, DOAD = digital obstructive artery disease, LDF = laser Doppler flowmetry, LSCI = laser speckle contrast imaging, MRA = magnetic resonance angiography, SBF = skin blood flow, US = color-duplex ultrasound.

Keywords: angiography, Buerger disease, laser Doppler flowmetry, laser speckle contrast imaging

Editor: N/A.

Written consent to publish was obtained from the patient.

Data sharing does not apply to this manuscript as no datasets were generated or analyzed in the current observation.

The authors do hereby declare that all illustrations and figures in the manuscript are entirely original and do not require reprint permission.

The authors have no conflicts of interest to disclose.

Supplemental Digital Content is available for this article.

^a Department of Vascular Medicine, Rennes University Hospital, Rennes, ^b Rennes 1 University, INSERM CIC-1414, Rennes Cedex, ^c Department of Vascular Medicine, Redon Hospital, Redon, ^d Radiology and Medical Imaging Department, Rennes University Hospital, Rennes, France.

* Correspondence: Loukman Omarjee, Vascular Physician and Clinical Immunologist, Department of Vascular Medicine and Investigation, Hôpital Pontchaillou – Rennes University Hospital, 2 rue Henri Le Guilloux Rennes, F-35033, France (e-mail: loukmano@yahoo.fr).

Copyright © 2018 the Author(s). Published by Wolters Kluwer Health, Inc. This is an open access article distributed under the terms of the Creative Commons Attribution-Non Commercial-No Derivatives License 4.0 (CCBY-NC-ND), where it is permissible to download and share the work provided it is properly cited. The work cannot be changed in any way or used commercially without permission from the journal.

Medicine (2018) 97:43(e12979)

Received: 20 June 2018 / Accepted: 4 October 2018

<http://dx.doi.org/10.1097/MD.00000000000012979>

1. Introduction

Buerger disease (BD) is a nonatherosclerotic, inflammatory, segmental vascular occlusive disease, which affects small and medium-sized arteries and veins and is triggered by substantial tobacco exposure.^[1] The clinical presentations of BD are Raynaud phenomenon, ischemic ulcers, and gangrene in the upper and lower extremities and superficial vein thrombosis.^[1,2] Diagnosis is based on clinical and angiographic findings, including age (<50 years), history of smoking and/or cannabis, and distal extremity ischemia.^[1,3] Angiographic findings consistent with BD are required for diagnosis according to *Olin, Shionoya, and Papa*.^[1,3,4] A typical but nonpathognomonic pattern including smooth noncalcified vessels, vasospasm, distally located multisegmental vessel occlusion, cutoff occlusion, corkscrew collateral vessels, and no-reflow phenomenon in the original vessel.^[1]

This pattern could also be identified by color-duplex ultrasound (US), magnetic resonance angiography (MRA), and computed tomography angiography (CTA) but in some very distal lesions these techniques lack sensitivity for BD diagnosis due to insufficient resolution, thus necessitating more sensitive alternative techniques. Among these techniques, combined laser Doppler flowmetry (LDF) and laser speckle contrast imaging (LSCI) are a potential alternative to angiography.

2. Case report

We report the case of a 49-year-old smoker with no medical history who was referred to the Rennes Vascular Medicine Consultation Center for investigation and management of an ischemic ulcer in the distal segment of the second finger of the left hand. He had no history of major cardiovascular events, no diabetes mellitus, no arterial hypertension, no dyslipidemia, and no superficial vein or arterial thrombosis. Hand examination revealed necrosis of the left index involving bilateral Raynaud phenomenon (Fig. 1). No sclerodactily, puffy fingers, pitting scars, telangiectasia, pterygium inversus unguis, or Gottron papules were observed. Cardiac examination was normal, as were ECG/echocardiographic findings. Upper-limbs arteries US and CTA of the aorta and upper limbs arteries were unremarkable, ruling out embolic etiology. Laboratory tests revealed no significant abnormalities (no inflammatory syndrome and excluded other etiologies of digital ulcers such as diabetes, connective tissue disease especially systemic sclerosis and dermatomyositis, vasculitis, congenital, or acquired thrombophilia especially antiphospholipid syndrome). In our vascular center, LDF and LSCI are conducted routinely for digital artery disease diagnosis according to the previous literature.^[5,6] In this patient, LDF measurements were performed on each finger: baseline skin blood flow (SBF) at room temperature and postwarming skin blood flow. LDF was indicative of digital obstructive artery disease (DOAD) when postwarming SBF was <206 arbitrary units (a.u.).^[5] LDF sensitivity and specificity were 93% (95% confidence interval, 85%–97%) and 96% (95% confidence interval, 90%–99%) when diagnosing DOAD. In this instance, all fingers had SBF values <206 a.u. Furthermore, cutaneous blood flow on the dorsal side of the hand measured by LSCI (PeriCam PSI System; Perimed, Järfälla, Sweden) revealed postocclusive hyperemia.^[6] SBF was occluded for 3 minutes by inflating a cuff placed on the right upper arm to 50 mm Hg above the patient's systolic blood pressure^[6] (Fig. 2; Video 1, <http://links.lww.com/MD/C583> [Video 1: Laser Speckle Contrast Imaging recorded during rest-, ischemic-, and release of occlusion phases.]). Postocclusive reactive hyperemia demonstrated no SBF perfusion in the distal phalanx of the thumb, index, middle, and

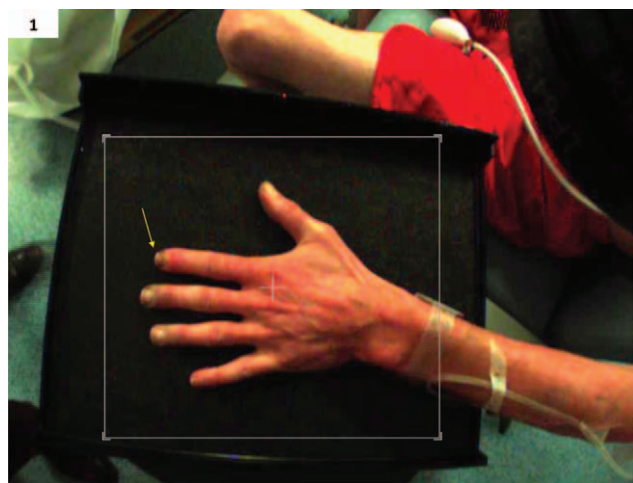


Figure 1. Left hand of a 49-year-old smoker before measurement of blood flow perfusion by laser speckle contrast imaging. Note the presence of Raynaud phenomenon and an ischemic ulcer in the distal segment of the second finger of the left hand (arrows).




Figure 2. Laser speckle contrast imaging recorded during the ischemic phase: baseline blood flow was recorded over the 2 min before initiating ischemia. Skin blood flow was occluded for 3 min by inflating a cuff placed on the right upper arm to 50 mm Hg above the patient's systolic blood pressure. No skin perfusion (blue color) of the whole left hand was recorded.

auricular fingers (Fig. 3; Video 1, <http://links.lww.com/MD/C583> [Video 1: Laser Speckle Contrast Imaging recorded during rest-, ischemic-, and release of occlusion phases.]). Angiography confirmed BD, showing distally located multisegmental vessel occlusion and corkscrew collaterals in this patient's hands (Fig. 4; Video 2, <http://links.lww.com/MD/C584> [Video 2: Angiography of the left hand recorded before, during and after contrast injection.]). Consequently, BD was diagnosed and Ilomedine treatment was initiated at a dose of 1 ng/Kg/min intravenously over a period of 6 hours for 28 days. Smoking cessation was definitive, inducing an improvement in clinical condition thus far despite the persistence of a small zone of necrosis of the left index finger 28 days post-treatment.

3. Discussion

Diagnosis of BD is usually made in young patients (<50 years) with evidence of small- or medium-sized arterial occlusive disease

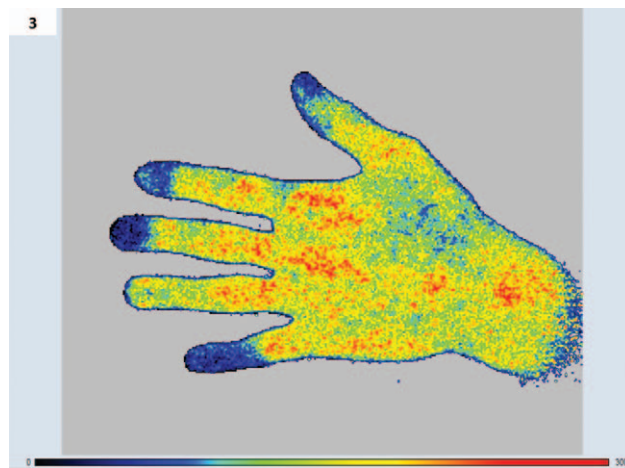


Figure 3. Laser speckle contrast imaging recorded during release of occlusion phase: after release of occlusion, the data were recorded for 10 min to obtain late phase of reactive hyperemia. Postocclusive reactive hyperemia showed absence of skin blood flow perfusion (blue color) in the distal phalanx of the thumb, index, middle, and little fingers.

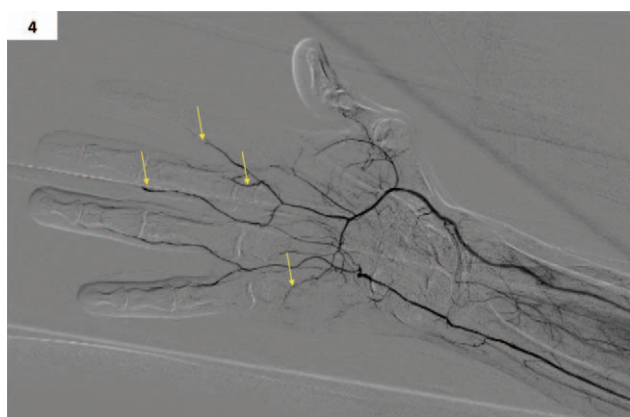

Figure 4. Angiography of the left hand, showing typical angiographic patterns of Buerger disease such as distally located multisegmental vessel occlusion, cutoff occlusion, and corkscrew collaterals (arrows). Note the absence of calcification, severe stenosis, and thrombosis in the large and medium arteries.

involving the upper and lower extremities, and in whom other conditions causing small vessel occlusive disease have been excluded.^[1]

Several criteria have been proposed for the diagnosis of BD.^[1,3] Noninvasive imaging techniques such as CTA and MRA do not provide sufficient spatial resolution to demonstrate many of the characteristic findings of BD. Therefore, angiography is generally the preferred modality for investigation in these patients but is invasive and expensive. LDF is a common technique for assessment and quantification of blood perfusion in the research field.^[7] This technique is also used in clinical practice for toe-pressure measurements.^[8] In 2014, the authors from the Mayo Clinic have published a study showing the interest of using the LDF in clinical practice to assess DOAD.^[5] In this study, they have shown that LDF coupled with a thermal provocation test has a high sensitivity to 93% (95% confidence interval, 85%–97%) and specificity to 96% (95% confidence interval, 90%–99%) to detect DOAD assessed by angiography.^[5] However it is well known that the LDF suffers from a poor spatial reproducibility since only 1 mm³ is measured.^[5] To face this issue, the LCSI has been proposed. LSCI is an emerging noninvasive microvascular imaging modality providing real-time dynamic assessment of total blood perfusion at various skin areas.^[6] Several studies have shown that LSCI has a better reproducibility than LDF.^[9–11] To date, LSCI has been shown of interest in secondary Raynaud phenomenon due to systemic sclerosis but no study has shown the interest of the use of LSCI in BD.^[12] We decided to add LSCI to LDF assessment since LDF's cutoff to diagnose DOAD was previously validated and the use of LSCI to study the whole microcirculation of the hand.

Our observation suggests that when there is a suspicion of BD based on clinical criteria,^[1,3] combining LDF and LSCI could

represent a noninvasive, safe means of reaching BD diagnosis. Further clinical trials are necessary to confirm this novel observation.

Acknowledgment

The authors thank Mrs Hazel Chaouch (hctranslationservice@outlook.com) for the formatting of the article and English language correction.

Author contributions

Conceptualization: Loukman Omarjee, Guillaume Mahe.

Data curation: Loukman Omarjee, Antoine larralde, Vincent Jaquinandi, Olivier Stivalet, Guillaume Mahe.

Formal analysis: Loukman Omarjee.

Investigation: Loukman Omarjee.

Methodology: Loukman Omarjee, Antoine Larralde, Guillaume Mahe.

Supervision: Vincent Jaquinandi, Olivier Stivalet.

Validation: Loukman Omarjee, Antoine Larralde, Vincent Jaquinandi, Olivier Stivalet, Guillaume Mahe.

Writing – original draft: Loukman Omarjee.

Loukman OMARJEE orcid: 0000-0001-7766-396X.

References

- [1] Olin JW. Thromboangiitis obliterans (Buerger's disease). *N Engl J Med* 2000;343:864–9.
- [2] Padilla LG, Fernández RR. Digital ischemia and tobacco. *Pan Afr Med J* 2017;27:104.
- [3] Shionoya S. Diagnostic criteria of Buerger's disease. *Int J Cardiol* 1998;66(suppl 1):S243–245.
- [4] Papa MZ, Rabi I, Adar R. A point scoring system for the clinical diagnosis of Buerger's disease. *Eur J Vasc Endovasc Surg* 1996;11:335–9.
- [5] Mahe G, Liedl DA, McCarter C, et al. Digital obstructive arterial disease can be detected by laser Doppler measurements with high sensitivity and specificity. *J Vasc Surg* 2014;59:1051–7.
- [6] Mahé G, Humeau-Heurtier A, Durand S, et al. Assessment of skin microvascular function and dysfunction with laser speckle contrast imaging. *Circ Cardiovasc Imaging* 2012;5:155–63.
- [7] Corrêa MJU, Perazzio SF, Andrade LEC, et al. Quantification of basal digital blood flow and after cold stimulus by laser Doppler imaging in patients with systemic sclerosis. *Rev Bras Reumatol* 2010;50:128–40.
- [8] Høyer C, Sandermann J, Paludan JPD, et al. Diagnostic accuracy of laser Doppler flowmetry versus strain gauge plethysmography for segmental pressure measurement. *J Vasc Surg* 2013;58:1563–70.
- [9] Puissant C, Abraham P, Durand S, et al. Reproducibility of non-invasive assessment of skin endothelial function using laser Doppler flowmetry and laser speckle contrast imaging. *PLoS One* 2013;8:e61320.
- [10] Roustit M, Millet C, Blaise S, et al. Excellent reproducibility of laser speckle contrast imaging to assess skin microvascular reactivity. *Microvasc Res* 2010;80:505–11.
- [11] Humeau-Heurtier A, Guerreschi E, Abraham P, et al. Relevance of laser Doppler and laser speckle techniques for assessing vascular function: state of the art and future trends. *IEEE Trans Biomed Eng* 2013;60:659–66.
- [12] Gaillard-Bigot F, Roustit M, Blaise S, et al. Abnormal amplitude and kinetics of digital postocclusive reactive hyperemia in systemic sclerosis. *Microvasc Res* 2014;94:90–5.