



HAL
open science

Management of epithelial cancer of the ovary, fallopian tube, and primary peritoneum. Long text of the Joint French Clinical Practice Guidelines issued by FRANCOGYN, CNGOF, SFOG, and GINECO-ARCAGY, and endorsed by INCa. Part 1 Diagnostic exploration and staging, surgery, perioperative care, and pathology

V Lavoue, C Huchon, C Akladios, P Alfonsi, N Bakrin, M Ballester, S Bendifallah, P A Bolze, F Bonnet, C Bourgin, et al.

► **To cite this version:**

V Lavoue, C Huchon, C Akladios, P Alfonsi, N Bakrin, et al.. Management of epithelial cancer of the ovary, fallopian tube, and primary peritoneum. Long text of the Joint French Clinical Practice Guidelines issued by FRANCOGYN, CNGOF, SFOG, and GINECO-ARCAGY, and endorsed by INCa. Part 1 Diagnostic exploration and staging, surgery, perioperative care, and pathology. *Journal of Gynecology Obstetrics and Human Reproduction*, 2019, 48 (6), pp.369-378. 10.1016/j.jogoh.2019.03.017 . hal-02121102

HAL Id: hal-02121102

<https://hal-univ-rennes1.archives-ouvertes.fr/hal-02121102>

Submitted on 29 May 2019

HAL is a multi-disciplinary open access archive for the deposit and dissemination of scientific research documents, whether they are published or not. The documents may come from teaching and research institutions in France or abroad, or from public or private research centers.

L'archive ouverte pluridisciplinaire **HAL**, est destinée au dépôt et à la diffusion de documents scientifiques de niveau recherche, publiés ou non, émanant des établissements d'enseignement et de recherche français ou étrangers, des laboratoires publics ou privés.

Management of epithelial cancer of the ovary, fallopian tube, and primary peritoneum. Long text of the Joint French Clinical Practice Guidelines issued by FRANCOGYN, CNGOF, SFOG, and GINECO-ARCAGY, and endorsed by INCa. (Part 1: diagnostic exploration and staging, surgery, perioperative care, and pathology)

Lavoue V^{1*}, **Huchon C**², Akladios C³, Alfonsi P⁴, Bakrin N⁵, Ballester M⁶, Bendifallah S⁷, Bolze PA⁸, Bonnet F⁹, Bourgin C¹⁰, Chabbert-Buffet N⁷, Collinet P¹⁰, Courbiere B¹¹, De la motte rouge T¹², Devouassoux-Shisheboran M¹³, Falandry C¹⁴, Ferron G¹⁵, Fournier L¹⁶, Gladieff L¹⁷, Golfier F⁸, Gouy S¹⁸, Guyon F¹⁹, Lambaudie E²⁰, Leary A²¹, Lecuru F²², Lefrere-Belda MA²³, Leblanc E²⁴, Lemoine A⁹, Narducci F²⁴, Ouldamer L²⁵, Pautier P²¹, Planchamp F²⁶, Pouget N²⁷, Ray-Coquard I²⁸, Rousset-Jablonski C²⁸, Senechal-Davin C¹⁹, Touboul C²⁹, Thomassin-Naggara I³⁰, Uzan C³¹, You B³², **Darai E**⁷.

Affiliations :

1. Service de gynécologie, CHU de Rennes, Hôpital sud, 16 Bd de Bulgarie 35000 Rennes, France. INSERM 1242, Chemistry, Oncogenesis, Stress and Signaling, Centre Eugène Marquis, Rue Bataille Flandres-Dunkerques, Rennes, France.
2. Service de Gynécologie, CHI Poissy, France.
3. Service de Gynécologie, Hôpital Hautepierre, CHU Strasbourg, France
4. Service d'Anesthésie, Hôpital Saint Joseph, Paris, France.
5. Service de chirurgie digestive, CHU Lyon-Sud, Pierre-Bénite, Lyon, France.
6. Service de gynécologie, GH Diaconesses Croix Saint Simon, Paris, France.

7. Service de Gynécologie-Obstétrique et Médecine de la Reproduction, Hôpital Tenon, 4 rue de La Chine, APHP, Institut Universitaire de Cancérologie Sorbonne Université, UMRS-938.
8. Service de chirurgie gynécologique, CHU Lyon-Sud, Pierre Bénite, Lyon, France.
9. Service d'anesthésie, Hôpital Tenon, AP-HP, Paris, France
10. Service de Chirurgie Gynécologique, Hôpital Jeanne de Flandres, CHRU, Lille, France
11. Pôle Femmes-Parents-Enfants – Centre Clinico-Biologique d'AMP, AP-HM La Conception, 147 bd Baille, 13005 Marseille / Aix Marseille Université, CNRS, IRD, Avignon Université, IMBE UMR 7263, 13397, Marseille, France
12. Service d'oncologie médicale, Centre Eugène Marquis, Rennes, France.
13. Service d'anatomo-pathologie, Hospices civiles de Lyon, CHU Lyon-Sud, Pierre-Bénite, Lyon, France.
14. Service d'oncogériatrie, Hospices civiles de Lyon, CHU Lyon-Sud, Pierre-Bénite, Lyon, France.
15. Service d'oncologie chirurgicale, Institut Claudius Regaud, IUCT Oncopole, Toulouse, France.
16. Service de radiologie, Hôpital Européen Georges Pompidou, AP-HP, Paris.
17. Service d'oncologie médicale, Institut Claudius Regaud, IUCT Oncopole, Toulouse, France.
18. Service de chirurgie, Institut Gustave Roussy, Villejuif, France.
19. Service de chirurgie, Institut Bergonié, Bordeaux, France.
20. Service de chirurgie, Institut Paoli Calmette, Marseille, France.
21. Service d'oncologie médicale, Institut Gustave Roussy, Villejuif, France.
22. Service de chirurgie gynécologique et oncologique, Hôpital Européen Georges Pompidou, AP-HP, Paris, France.

23. Service d'anatomo-pathologie, Hôpital Européen Georges Pompidou, AP-HP, Paris, France.
24. Service de chirurgie, Centre Oscar Lambret, Lille, France.
25. Service de chirurgie gynécologique, CHU de Tours, France.
26. Service de méthodologie, Institut Bergonié, Bordeaux, France.
27. Service de chirurgie, Curie (site Saint Cloud), Paris, France.
28. Service d'oncologie médicale, Centre Léon Bérard, Lyon, France.
29. Service de chirurgie gynécologique, CHI de Créteil, Créteil, France.
30. Service de radiologie, Hôpital Tenon, AP-HP, Paris, France.
31. Service de chirurgie et cancérologie gynécologique et mammaire, Hôpital Pitié Salpêtrière, Institut Universitaire de Cancérologie, Sorbonne Université, INSERM U938.
32. Service d'oncologie médicale, Institut de cancérologie des Hospices Civils de Lyon, Pierre-Bénite, Lyon, Paris.

*Auteur correspondant : Pr Vincent Lavoué, Service de chirurgie gynécologique, CHU Hôpital Sud, 16 Bd de Bulgarie, 35000 Rennes, France. Vincent.lavoue@chu-rennes.fr

Corresponding author: Pr Vincent LAVOUE. Vincent.lavoue@chu-rennes.fr. Service de chirurgie gynécologique. CHU Hôpital sud, 16 BD de Bulgarie, 35000 RENNES, FRANCE.

Summary:

An MRI is recommended for an ovarian mass that is indeterminate on ultrasound. The ROMA score (combining CA125 and HE4) can also be calculated (Grade A). In presumed early-stage ovarian or tubal cancers, the following procedures should be performed: an omentectomy (at a minimum, infracolic), an appendectomy, multiple peritoneal biopsies, peritoneal cytology (grade C), and pelvic and para-aortic lymphadenectomies (Grade B) for all histologic types, except the expansile mucinous subtypes, for which lymphadenectomies can be omitted (grade C). Minimally invasive surgery is recommended for early-stage ovarian cancer, when there is no risk of tumor rupture (grade B). For FIGO stages III or IV ovarian, tubal, and primary peritoneal cancers, a contrast-enhanced computed tomography (CT) scan of the thorax/abdomen/pelvis is recommended (Grade B), as well as laparoscopic exploration to take multiple biopsies (grade A) and a carcinomatosis score (Fagotti score at a minimum) (grade C) to assess the possibility of complete surgery (i.e., leaving no macroscopic tumor residue). Complete surgery by a midline laparotomy is recommended for advanced ovarian, tubal, or primary peritoneal cancer (grade B). For advanced cancers, para-aortic and pelvic lymphadenectomies are recommended when metastatic adenopathy is clinically or radiologically suspected (grade B). When adenopathy is not suspected and when complete peritoneal surgery is performed as the initial surgery for advanced cancer, the lymphadenectomies can be omitted because they do not modify either the medical treatment or overall survival (grade B). Primary surgery (before other treatment) is recommended whenever it appears possible to leave no tumor residue (grade B).

Key words: ovarian cancer; tubal cancer, primary peritoneal cancer, surgery; chemotherapy; guidelines

Introduction

Initial management of epithelial ovarian cancers is relatively heterogeneous in France, with treatment sequences that differ substantially between centers for primary or interval surgery. Similarly, the extent of surgery and the surgical staging procedures vary according to patient characteristics (young vs elderly women, for example). Perioperative management, whether it concerns early recovery or fertility preservation, has not been standardized, although it can cause physical or psychological morbidity. Finally, cancer centers vary widely in their use of chemotherapy (and how they administer it), as well as of targeted therapies; a national strategy remains to be defined, according to different clinical contexts; a national strategy remains to be defined, according to different clinical contexts. Work to develop clinical practice guidelines is therefore necessary to enable practices to be in accordance with the best evidence and to improve prognosis for all patients.

Accordingly, the French research group for oncologic gynecologic surgery (FRANCOGYN), the French national college of gynecologists and obstetricians (CNGOF), the French society of gynecologic oncology (SFOG), and the national investigators' group for studies in ovarian and breast cancer (GINECO-ARCAGY) jointly brought together a working group to develop such guidelines. This text is a synthesis of clinical practice guidelines for the initial management of epithelial ovarian, tubal, or primary peritoneal cancers (excluding recurrence of ovarian cancer and borderline tumors).¹ The development of these clinical practice guidelines followed the standards set by the French national authority for health (HAS) and the national cancer institute (INCa), with reviews by experts both within and outside the working group.¹⁻³ INCa has endorsed these clinical practice guidelines.

This article deals with the role of diagnostic explorations, surgery, perioperative care, and pathology studies of women with ovarian, tubal, or primary peritoneal cancers.

Their aim is to aid professionals (gynecologic surgeons, medical gynecologists, gynecologist-obstetricians, pathologists, medical oncologists, radiologists, anesthetist-critical-care specialists, nuclear physicians, general practitioners, midwives and paramedical personnel) in managing women with ovarian cancer or with suspected ovarian, tubal, or primary peritoneal cancers.

Accepted Manuscript

Role of imaging in the exploration of an ovarian mass suspected to be ovarian cancer²
(Figure 1)

An adnexal mass is a tumor of the ovary or fallopian tubes detected by either a clinical or an imaging examination. **Transvaginal and transabdominal (suprapubic) ultrasound are recommended for the analysis of an isolated ovarian mass (grade A).**² **It is recommended that non-expert operators performing ultrasound use the Simple Rules (grade A). These rules must be combined with subjective analysis to equal the performance of expert ultrasonographers (grade A).** According to the Simple Ultrasound Rules (Table 1):

- The mass is classified as malignant if at least one M (malignant) rule applies and no B (benign) rule applies.
- The mass is classified as benign if at least one B rule applies and no M rule applies.
- It cannot be classified (or is indeterminate) if at least one M rule and one B rule both apply or if no rule applies.

Software is available without charge at the IOTA site (www.iotagroup.org), and an application is available for both Android and iOS. During the initial study, the simple rules were able to be applied in 76% of cases and the adnexal masses were correctly classified as benign or malignant with a sensitivity of 93% and a specificity of 90%; their positive and negative predictive values were 80% and 97% respectively. Around 25% of adnexal masses remain indeterminate with the Simple Rules and require a second-line examination.

When an adnexal mass is complex or indeterminate on ultrasound, a pelvic MRI is recommended (grade A). MRI has excellent specificity and makes it possible to classify as benign numerous complex masses indeterminate on ultrasound (LE1). **MRI to characterize an adnexal mass should use T2, T1, T1 Fat Sat, dynamic contrast-enhanced, diffusion-weighted, and gadolinium-enhanced sequences (grade B) to improve diagnostic**

sensitivity (grade B). Contrast-enhanced dynamic MRI has confirmed that the time-signal intensity contrast uptake curve for the solid tissue under study, compared with the myometrium as reference (type 1: progressively increasing curve with no plateau; type 2 time-signal intensity curve, with a plateau and moderate wall enhancement, and not earlier than the myometrium; type 3 time-signal intensity curve within solid tissue: a curve steeper than that of the adjacent myometrium) makes it possible not only to differentiate benign tumors from malignant neoplasms with a sensitivity of 94%, a specificity of 84%, and a diagnostic precision of 92%, but also to distinguish within the malignant neoplasms borderline tumors from invasive tumors with a sensitivity of 88%, a specificity of 80%, and a diagnostic precision of 84% (LE3). Scores, in particular the ADNEX MR score, have been generated to establish the risk of malignancy (LE3). **It is recommended that an MRI report characterizing an adnexal mass include a malignancy risk score (such as the ADNEX MR).** Moreover, the use of the apparent distribution coefficient (ADC) allows the differentiation of borderline from invasive tumors, in particular, of seromucinous borderline tumors from invasive cancers on endometriomas of endometrioid or clear cells. **A pathological hypothesis should be included in the MRI report of an adnexal mass (grade C).**

Diagnostic value of serum markers for a suspicious adnexal mass³

The diagnostic value of CA125 for an indeterminate ovarian mass to diagnose an epithelial ovarian cancer varies for sensitivity from 0.74 to 0.80, for specificity from 0.76 to 0.84, and for area under the ROC curve (AUC) from 0.85 to 0.88 (LE1). The diagnostic value of HE4 for an indeterminate ovarian mass to diagnose an epithelial ovarian cancer varies for sensitivity from 0.74 to 0.85, for specificity from 0.83 to 0.84, and for AUC from 0.82 to 0.89

(LE1). These sensitivity, specificity, and AUC values for CA 125 and serum HE4 are similar for the diagnosis of an ovarian mass that is indeterminate on ultrasound (LE1).

Circulating tumoral DNA and tumor-associated auto-antibodies perform worse than or not better than CA125 or serum HE4 (LE4, LE1, LE2 respectively) and are not recommended for the assessment of a suspected ovarian cancer (grade C). Data about the CA19.9 and ACE serum markers for the positive diagnosis of ovarian cancer are sparse and do not justify any guidelines for their use to assess an ovarian mass that is indeterminate on imaging.

Diagnostic scores, both clinical and based on laboratory tests, have been developed for ovarian masses indeterminate on ultrasound. The diagnostic value of the ROMA score (Risk of Ovarian Malignancy Algorithm) for an indeterminate ovarian mass varies for sensitivity from 0.79 to 0.82, for specificity from 0.76 to 0.84, and for AUC from 0.91 to 0.93 (LE1). The ROMA score is superior diagnostically to serum CA125 and serum HE4 assayed in isolation for an indeterminate adnexal mass (LE1).

The ROMA score (based on serum assays of HE4 and CA125) can be used for an adnexal mass that is indeterminate on ultrasound (grade A). The CNAM-TS (French national health insurance fund) does not reimburse the HE4 serum assay.

Other diagnostic scores (Copenhagen index (CPH-I) (LE4), the R-OPS score (LE3), and OVA500 (LE3)) have been proposed, but none are superior to ROMA for the diagnosis of an ovarian mass that is indeterminate on ultrasound, and they are not recommended.

Role of an intraoperative pathology examination of a suspicious ovarian mass⁴

Intraoperative analysis of an excised ovarian mass is effective for both benign and malignant tumors, with an agreement rate between the intraoperative and definitive examinations of 94% and 99%, respectively (LE2). It is, however, less effective for borderline ovarian tumors, very large tumors, and mucinous tumors: the agreement rate between intraoperative and definitive

examinations for borderline ovarian tumors is 73%, with 21% of tumors finally classified as malignant and 6% as benign (LE2). **When an adnexal mass is suspected to be an ovarian cancer, an intraoperative pathology examination can be performed to enable optimal surgical staging during a single surgical procedure and thus avoid the need for reintervention (grade B).**

Modalities of surgery for early-stage ovarian cancer⁵ (Figure 1)

Presumed early-stage epithelial ovarian cancer (< FIGO stage IIA, therefore limited to the internal genitalia) involves from 20 to 33% of the women with ovarian cancer. The rate of occult omental metastases in presumed early-stage ovarian cancer ranges from 2 to 4% depending on the study and results in up-staging 3% to 11% of women to stage IIIA. Performance of an omentectomy does not modify their survival (LE3). Reported rates of metastasis to the appendix in early-stage ovarian cancer range from 0 to 26.7% (LE3). In the mucinous subtype, this rate can reach 53% if the appendix is macroscopically abnormal (LE2). The rate of positive peritoneal cytology in FIGO stages I and II ovarian cancers varies in the literature from 20.9% to 27%. The performance of peritoneal cytology leads to up-staging in 4.3% to 52% of cases, and positive results are a poor prognostic factor (LE3). The rate of occult peritoneal metastases varies from 1.1% to 16%. Performance of these biopsies results in an up-staging of 4% to 7.1% (LE3). In early-stage ovarian cancer, the lymph node invasion rate ranges from 6.3% to 22% according to the literature. It is 4.5% to 18% for stage I and 17.5% to 31% in stage II. The literature does not report lymph node involvement in the histologic subtypes of expansile mucinous carcinoma (LE3). This rate ranges from 1.7% to 10.7% for low-grade serous carcinoma. From 8.5% to 13% of women with presumed early-stage ovarian cancer are reclassified as stage IIIA1 (FIGO2014) after the lymphadenectomy

(LE3). The performance of a pelvic and para-aortic lymphadenectomy improves survival in these women with presumed early-stage ovarian cancer (LE2).

In presumed early-stage ovarian cancer, the following procedures should be performed: an omentectomy (at a minimum, infracolic), an appendectomy, peritoneal biopsies, peritoneal cytology (grade C), and pelvic and para-aortic lymphadenectomies (Grade B) except for the expansile mucinous subtypes, for which the lymphadenectomies can be omitted.

If the initial staging was not performed or was incomplete (defined by any of: no omentectomy, no exploration or resection of the appendix, no pelvic or para-aortic lymphadenectomy or peritoneal biopsies) for a presumed early-stage ovarian cancer, surgical restaging is recommended, including omentectomy (at least infracolic) (grade C), appendectomy (grade C), pelvic and para-aortic lymphadenectomies (grade B) (except for expansile mucinous cancer), and peritoneal biopsies (grade C), especially in the absence of an indication for chemotherapy.

No studies examining either laparotomic or minimally invasive approaches have shown any disadvantage to the laparoscopic pathway compared with laparotomy for feasibility, oncologic safety, or postoperative recovery (LE3) in the surgical staging of women with presumed early-stage ovarian cancer. The benefits of the laparoscopic approach in terms of reduced intraoperative complications and accelerated postoperative recovery must be interpreted in the light of the various authors' laparoscopic experience. For the initial surgical management of early-stage ovarian cancer, the choice of approach depends on local conditions (tumor size, in particular) and surgical expertise. The published data show a reduction in recurrence-free survival (hazard ratio = 2.28) and overall survival (hazard ratio = 3.79) associated with intraoperative tumor rupture in early-stage ovarian cancer (FIGO stage IC1 if rupture) compared with no rupture (FIGO stage IA or IB) (LE2). The literature data do not currently

allow us to identify factors predictive of intraoperative tumor rupture, besides the presence of adhesions (LE4). No specific study answers the question about the benefit of surgery in 1 or 2 procedures when intraoperative diagnosis is performed for presumed early-stage ovarian cancer. Nonetheless, the high sensitivity and specificity of intraoperative pathology examination in this situation allows us to envision surgical staging in a single procedure if the intraoperative examination is positive.

In presumed early-stage ovarian cancer, a minimally invasive approach is recommended if complete surgery is possible without the risk of tumor rupture (grade B). Otherwise, a midline laparotomy is recommended (grade B). All precautions must be taken to avoid the intraoperative rupture of an ovarian tumor, including an intraoperative decision to convert to open surgery (grade B). For surgical restaging, a minimally invasive approach should be preferred when the ovarian mass has already been removed (grade B).

Pretreatment assessment of extension of carcinomatosis presumed to be of ovarian, tubal, or primary peritoneal origin²

A thorax/abdomen/pelvis CT scan makes it possible to assess the extent of carcinomatosis (LE2) and to specify the tumor sites that might compromise complete surgical resection (i.e., with no macroscopic tumor residue). The diagnostic performance of a PET-scan and MRI are inferior to that of CT for assessing peritoneal disease (LE2). The performance of a PET-scan is slightly better than those of CT and MRI for assessing lymph node involvement and diagnosing remote disease in ovarian, tubal, or primary peritoneal cancers (LE3).

A contrast-enhanced CT scan of the thorax/abdomen/pelvis is recommended for the preoperative workup of the extension and resectability of ovarian, tubal, or primary peritoneal carcinomatosis (grade B). The CT report should specify the presence of substantial ascites, the overall extent of the carcinomatosis, as well as involvement of the mesentery, the extended gastrointestinal tract, the lesser omentum, the hepatic hilum, suprarenal para-aortic adenopathy, abdominal parenchymal (hepatic etc.) or extra-abdominal metastases (umbilical or parietal, pulmonary, inguinal, or mediastinal lymph nodes).

If iodinated contrast agents are contraindicated (severe kidney failure, GFR < 30 mL/min, allergies), an abdominal/pelvic MRI supplemented by a CT scan without contrast enhancement can replace the thorax/abdomen/pelvis CT scan (grade C).

Data assessing the diagnostic performance of radiologic examinations to assess response to chemotherapy are sparse. **No guideline can be issued about the best type of imaging after neoadjuvant chemotherapy to assess the resectability of ovarian, tubal, or primary peritoneal carcinomatosis.**

The role of serum tumor markers in the initial management of advanced stage epithelial ovarian cancer³

Serum markers such as CA125 or a combination of CA125 and HE4 have been proposed to predict complete surgery (i.e., with no tumor residue). A CA125 threshold greater than 500 IU/mL has a sensitivity of 0.52 to 0.80 and a specificity of 0.40 to 0.89 for predicting no tumor residue after surgery (LE1). These mediocre performance levels, the low level of evidence in the literature, and the absence of a uniform threshold specific for these markers

for predicting no tumor residue after interval surgery (after neoadjuvant chemotherapy) — together they prevent us from offering a recommendation about the use of these markers to influence treatment strategy in women with ovarian cancer.

Role of laparoscopy and scores to assess resectability in ovarian, tubal, and primary peritoneal carcinomatosis³ (Figures 2 and 3)

Laparoscopy to assess ovarian, tubal, or primary peritoneal carcinomatosis reduces by 30% the number of laparotomies leading to nonoptimal surgery (i.e., tumor residue exceeding 1 cm) (LE1). **Laparoscopy is recommended to assess the feasibility of surgical resection that leaves no macroscopic tumor residue (i.e., complete surgery) in a woman with ovarian, tubal, or primary peritoneal carcinomatosis before laparotomic surgery (grade A).**

Several scores for assessing the extension of peritoneal carcinomatosis have been developed. The Fagotti score is a laparoscopic score based on 7 indicators rated 0 or 2 (Table 3).

With a Fagotti score ≥ 8 , the probability of complete primary surgery at the laparotomy (i.e., no tumor residue) was 8.3% and the rate of futile exploratory laparotomy was 28.3%. With a Fagotti score ≥ 10 , the probability of complete primary surgery at the laparotomy was 0% and that of futile exploratory laparotomy 33.2% (NP4). The Fagotti score is also useful in a situation of interval surgery after neoadjuvant chemotherapy. A score ≥ 4 shows a zero probability of optimal interval surgery and enables a 17% reduction in the number of nonoptimal laparotomies (LE4). **For women with ovarian, tubal, or primary peritoneal carcinomatosis, the use of a carcinomatosis score (at least the Fagotti score) during laparoscopy is recommended to assess the risk of nonresectability during primary or interval surgery (grade C). A Fagotti score ≥ 8 is correlated with a low rate of complete**

primary surgery (LE4). A Fagotti score ≥ 4 is correlated with a low rate of complete interval surgery (LE4).

A modified Fagotti score, reduced to four criteria graded 0 or 2 for diaphragmatic carcinomatosis, mesenteric retraction, gastric infiltration, and hepatic metastases has also been proposed, with a threshold ≥ 4 for predicting nonresectability. Its performance does not appear to be inferior to that of the 7-criteria Fagotti score, but because it has been less widely evaluated, it cannot currently be recommended.

Several scores for laparotomic assessment of tumor/carcinomatosis extension have been described: The Sugarbaker score or the PCI (Peritoneal Cancer Index), which divides the abdomen into 13 regions with a score of 0 to 3 according to the size of the tumor implants (total score range: 0 to 39) and the Eisenkop score, which divides the abdomen into 5 regions scored 0 to 3 (total score range: 0 to 15). Finally, the Aletti score assesses surgical complexity, with a score of 1 to 3 for each surgical procedure as a function of its complexity (score range: 0 to 18), correlated with the risk of postoperative complications. An external validation found the PCI score best for predicting the optimal surgery for all FIGO stages combined. **In women undergoing laparotomy for ovarian, tubal, or primary peritoneal carcinomatosis, use of the Peritoneal Cancer Index (PCI) is recommended to assess the tumor burden (grade C).**

Surgery for advanced ovarian, tubal, or primary peritoneal cancer (FIGO stages IIB to IV)⁶ (Figures 2 and 3)

The tumor residue after primary or interval surgery is an essential prognostic factor, regardless of histologic type (serous or other, high or low grade) (LE2). A higher volume of surgery for ovarian cancer per surgeon (≥ 10 /year) and per hospital (≥ 20 /year) increases the complete surgery rate, reduces postoperative morbidity and mortality, and thus improves

patient prognosis (LE3). Adjuvant chemotherapy started more than 6 weeks after surgery negatively influences recurrence-free and overall survival (LE3).

Complete surgery (i.e., with no macroscopic tumor residue) of advanced ovarian, tubal, or primary peritoneal cancer is recommended (Grade B). Surgery for ovarian cancer should be performed in a high-volume hospital (defined by performance of at least 20 procedures for advanced ovarian cancer each year) (Grade C). Adjuvant chemotherapy should begin within 6 weeks after surgery for ovarian, tubal, or primary peritoneal cancer (Grade C).

In women with FIGO stage IV ovarian, tubal, or primary peritoneal cancer, pleural or pulmonary metastases have been observed in 41% of cases, abdominal wall metastasis in 40%, metastases in lymph nodes other than the pelvic and para-aortic in 19%, and hepatic metastases in 14%. Complete abdominal and peritoneal cytoreduction surgery (i.e., with no macroscopic tumor residue) is superior to surgery called optimal (i.e., leaving a tumor residue < 1 cm), which itself is superior to surgery leaving residues greater than a centimeter, which in turn is not superior to no surgery; median recurrence-free survival was respectively 50, 25, 16, and 19 months (LE4). For cytoreduction surgery, resection penetrating the diaphragm is associated with significantly more postoperative morbidity than stripping the diaphragmatic dome (LE4). **In FIGO stage IV ovarian, tubal, and primary peritoneal cancer, surgery is recommended when a complete peritoneal abdominal resection (i.e., with no macroscopic tumor residue) is possible (grade C).**

Three published meta-analyses, including both published cohorts and 3 randomized trials, have assessed the systematic surgical dissection of pelvic and para-aortic lymph nodes in advanced cancer (LE2). They show a benefit from systematic dissection with an improvement in overall survival (HR=0.74; 95% CI 0.59-0.94, $P=0.01$) including for the operations considered optimal (i.e., with tumor residue 1 cm or less in maximum diameter).

Nonetheless, the only prospective randomized trial (Panici et al.) currently published concerning advanced stages (and included in these meta-analyses) found no improvement in 5-year overall survival but only a prolongation of recurrence-free survival (LE2). These data are consistent with the published abstract of the LION trial presented at ASCO in 2017, which randomized women with ovarian carcinomatosis and no observed adenopathy (not visible on CT nor palpable at primary surgery after complete resection) to either systematic dissection or no dissection. This study found an identical overall survival rate among women who did and did not have dissections among the selected population, i.e., women with neither radiologic nor clinical adenopathy (LE2). On the other hand, benefits for both overall and recurrence-free survival were observed for systematic dissections when clinically or radiologically suspicious lymph nodes were present (LE2).

In advanced ovarian, tubal, or primary peritoneal cancer with no macroscopic tumor residue at the end of surgery, para-aortic and pelvic lymphadenectomies are recommended when metastatic adenopathy is suspected, either clinically or radiologically (Grade B). In the absence of such suspected adenopathy and when complete peritoneal surgery is performed as the initial surgery for advanced ovarian, tubal, or primary peritoneal cancers, the lymphadenectomies can be omitted because they do not modify either the medical treatment or overall survival (grade B). The other lymphadenectomies (suprarenal, mesenteric, laparoscopic hepatic, cardiophrenic angle) are not recommended in the absence of clinical invasion (grade C). Finally, it is not possible to make particular recommendations about the role of dissection according to histologic subtype or grade, due to the lack of data.

The treatment sequences of primary cytoreductive surgery and then adjuvant chemotherapy *vs* neoadjuvant chemotherapy and interval surgery after 3 or 4 treatments have not shown differences for overall or progression-free survival (LE1) (Table 4). In a meta-

analysis by Bristow, after three cycles of preoperative chemotherapy, each supplementary cycle was significantly associated with a 4.1-month reduction in women's median duration of survival ($P=0.046$). The interval surgery strategies have shown a significant diminution of morbidity and mortality and an improved quality of life, especially in the advanced stages with a high tumor burden (LE2). The 5-category classification by Makar et al. is useful for assessing the tumor burden in FIGO stage III carcinomatosis (LE2):

- Category 1: The tumor is localized in the pelvis, with little or no ascites and no need for gastrointestinal resection. Primary cytoreductive surgery is recommended

- Category 2: The tumor is localized in the pelvis, with little or no ascites. Gastrointestinal resection is necessary for complete cytoreduction. Primary cytoreductive surgery is recommended

- Category 3: A large portion of the tumor is localized in the supramesocolic space, with little or no ascites. No gastrointestinal resection is needed. Primary cytoreductive surgery is recommended

- Category 4: A large portion of the tumor is localized in the supramesocolic space, with little or no ascites. Gastrointestinal resection is necessary for complete cytoreduction. Primary cytoreductive surgery is recommended. In cases of impaired general condition, comorbidities, or advanced age, interval surgery can instead be envisioned after 3 cycles of neoadjuvant chemotherapy.

- Category 5: A very large portion of the tumor is localized in the supramesocolic space, with abundant ascites or miliary patterns on the mesentery. Initial cytoreduction may require several gastrointestinal resections. Neoadjuvant chemotherapy is recommended. Primary surgery is not contraindicated for FIGO stage 4 disease.

Neoadjuvant chemotherapy and then interval surgery are recommended for multiple intrahepatic masses, or pulmonary metastases, or substantial ascites with miliary patterns (LE1).

In advanced ovarian, tubal, or primary peritoneal carcinomatosis, primary surgery is recommended when it appears that complete surgery (i.e., no macroscopic tumor residue in the abdomen) is possible on condition that the surgery is acceptable in terms of morbidity, given both the complexity of the procedure and the patient's comorbidities (grade B). If complete cytoreduction (no tumor residue) does not appear possible, neoadjuvant chemotherapy should be offered, to be followed by interval surgery (Grade B) after 3 or 4 courses of chemotherapy (grade C). Makar's five categories are useful for choosing between primary surgery and interval surgery after neoadjuvant chemotherapy as the treatment strategy (grade C).

The specific histologic subtype is important: chemotherapy response is significantly poorer in low-grade compared to high-grade serous carcinomas (23.1% vs 90.1%) (LE3). Indirect data also show that the mucinous and clear-cell histologic subtypes respond less well to chemotherapy by platinum compounds and taxanes. **For advanced ovarian, tubal, and primary peritoneal cancers of particular histologic subtypes (mucinous, clear-cell, and low-grade serous), primary surgery should be preferred over neoadjuvant chemotherapy when complete resection is possible from the start (grade C).**

No guidelines can be issued about the type of procedure to perform for palliative surgery, or after the intraoperative recognition of the impossibility of complete (no macroscopic tumor residue) surgery in a patient with FIGO stage III or IV cancer after neoadjuvant chemotherapy. Any surgical procedure performed must be the least morbid possible.

Feasibility studies for the minimally invasive approach, as either primary or interval surgery, can help to choose between the xiphopubic midline laparotomy or a minimally invasive

approach, robot-assisted or not; no oncologic safety data (effect on survival) are available, however. The minimally invasive approach for primary surgery for advanced cancer (carcinomatosis) appears risky, but the data are sparse; this approach does seem possible for interval surgery with a complete biochemical and radiologic response to chemotherapy, but no guideline is justified. The benefit expected from the minimally invasive approach is a shorter length of stay and a better quality of life. Surgery by xiphopubic laparotomy for advanced ovarian, tubal, or primary peritoneal cancer remains the standard, as primary or interval surgery.

The surgical report for cytoreduction of advanced ovarian, tubal, or primary peritoneal cancer **should assess the tumor burden (grade C) according to the PCI (Peritoneal Cancer Index) score** and should indicate the reasons for tumor nonresectability if no cytoreduction surgery was performed, indicate if the surgery was complete, and state the size and site of any tumor residue. Use of a standardized surgical report is helpful.

Perioperative prehabilitation for and recovery from ovarian cancer surgery⁷*Preoperative management*

An intervention for epithelial ovarian cancer is major visceral surgery. It is accordingly eligible for a program of enhanced recovery after surgery (ERAS). These programs include measures of pre-, intra- and postoperative supportive care aimed at facilitating the patient's return to autonomy and at reducing the postoperative complication rate.

Moderate or severe malnutrition is frequent in women with ovarian cancer, especially carcinomatosis. The existence of such malnutrition before surgery promotes the onset of postoperative complications and reduces overall survival (LE2). Nonetheless, no study has yet assessed the benefits of correction of nutritional deficiencies on perioperative morbidity. There are no data about the benefits of immunonutrition in ovarian cancer. Similarly, anemia before surgery is frequent and appears to be a factor associated with a poorer survival prognosis (LE3), but no ovarian cancer-specific data about the benefits of its preoperative correction exist.

For women with ovarian, tubal, or primary peritoneal cancer, screening is recommended before surgery for nutritional deficiencies (Grade B) and anemia (grade C). No data justify recommendations about preoperative correction of nutritional deficiencies, immunonutritional deficiencies, or anemia in women with ovarian, tubal, or primary peritoneal cancers.

In the absence of data specific to surgery for ovarian cancer, it appears useful to refer to the guidelines issued by the French-speaking society of clinical nutrition and metabolism (SNFEP) and the French society for anesthesia-intensive care (SFAR).

Bowel preparation before the intervention is a recurrent question when a segment of the colon or rectum appears likely to be the object of total or partial resection in gastrointestinal or

gynecologic oncology. Its aim is to reduce both the risk of anastomotic complications and the indications for protection by a temporary stoma. This preparation may be a no/low residue diet for 7 days, or mechanical preparation (osmotic solution) and/or a rectal enema, and/or preoperative antibiotic therapy. These different types of bowel preparation have been studied particularly in gastrointestinal surgery through randomized trials and meta-analyses, which report that mechanical preparation appears futile for elective colon surgery, but is indicated for rectal surgery. Surgery for ovarian cancer differs from colorectal surgery because it most often involves peritoneal cytoreduction, which often requires en bloc rectosigmoid resection (Hudson's extraperitoneal posterior pelvic exenteration), associated with other abdominal procedures. There are currently no data in the specific context of ovarian cancer about the benefits of preoperative bowel preparation. **Similarly, no specific data about these ovarian, tubal, or primary peritoneal cancers justify guidelines for preoperative bowel preparation.**

Intraoperative management

A study has shown that monitoring total blood volume in women with advanced ovarian cancer shortens the postoperative length of stay necessary for discharge home (LE2). No benefit was found, however, for women undergoing surgery for early-stage ovarian cancer.

For women with advanced ovarian, tubal, or primary peritoneal cancers, individualized monitoring to ensure intraoperative goal-directed fluid management is recommended (Grade B).

A randomized study has shown that infusion of a single dose of tranexamic acid moderately reduces blood loss in women undergoing surgery for ovarian cancer. A positive impact on the need for transfusion has not been shown (NP2).

Women undergoing surgery for ovarian, tubal, or primary peritoneal cancer may be offered an infusion of a single dose of tranexamic acid to reduce intraoperative blood loss (Grade C).

Women with epidural analgesia have lower levels of postoperative pain, both at rest and on coughing, than those receiving intravenous opioid analgesia (LE2). On the other hand, no relation can be established between epidural use and prognosis or medium-term postoperative survival. In the absence of an epidural, analgesia can be provided by morphine with a patient-controlled pump. This analgesia is optimal as a bolus without continuous flow.

Epidural analgesia, in addition to general anesthesia, is recommended for the management of women undergoing laparotomic cytoreduction surgery for ovarian, tubal, or primary peritoneal cancer (Grade B). In the absence of epidural analgesia, patient-controlled administration of morphine is recommended, but without a continuous flow (Grade B).

No data justify a recommendation about intravenous administration of lidocaine or ketamine during surgery or the perioperative prescription of gabapentine or pregabalin.

Postoperative management

Early oral feeding reduces the time until return of normal bowel function and the length of hospitalization. It also increases patient satisfaction. Early oral feeding does not increase the postoperative complication rate, including after intestinal resection (LE2). Early mobilization helps reduce the length of stay. If rapid oral feeding is impossible, the use of chewing gum can be proposed to accelerate the resumption of transit and to reduce the length of hospitalization, but there are no data specific to ovarian cancer (LE3).

Early oral feeding is recommended, including after gastrointestinal resection for ovarian, tubal, or primary peritoneal cancer (Grade B).

Implementation of an ERAS protocol for major gynecologic surgery, combining no bowel preparation, a shorter fasting period, the absence of a nasogastric tube, smaller incisions and reduced use of drainage, monitoring intraoperative fluid management, early oral feeding, and early mobilization, has been shown to reduce length of postoperative stay without significantly reducing morbidity (LE4). **The establishment of protocols for enhanced recovery after surgery (ERAS), including early mobilization, is recommended to reduce the length of stay after surgery for ovarian, tubal, and primary peritoneal cancer (Grade C).**

1

2 **Role of biopathology (pathology, intraoperative pathology examination, and**
3 **biomarkers) in the management of ovarian, tubal, and primary peritoneal carcinomas⁴**

4 No studies of women with peritoneal carcinomatosis of presumably ovarian, tubal, or primary
5 peritoneal origin have assessed the number, site, and size of the laparoscopic samples
6 necessary for histologic diagnosis. The demonstration of tumor heterogeneity at the genomic
7 level in ovarian, tubal, or primary peritoneal carcinomatoses indicates the need to take
8 multiple laparoscopic samples at different tumor sites (LE4). Cytologic examination has good
9 sensitivity for the diagnosis of malignancy, but does not allow the histologic subtypes or
10 carcinoma grade to be established (LE3). The use of a paraffin-embedded pellet (cytoblock)
11 increases the sensitivity of cytology as a diagnostic test (LE4). The ratio of noncontributory
12 biopsies among radioguided biopsies of carcinomatosis lesions is higher with 18G needles
13 than with needles with a larger diameter (LE3). Most studies have considered 2 to 5 (mean 3)
14 biopsies per tumor (LE3). An immunohistochemical study of a preoperative biopsy increases
15 the rate of agreement between the diagnosis of the histologic type of ovarian carcinoma and
16 the final diagnosis (LE3). The postchemotherapy modifications impair the morphologic
17 appearance of tumor cells and thus prevent the correct establishment of the histologic subtype
18 of the carcinoma (LE4). Different immunohistochemical studies before and after
19 chemotherapy do not show post-treatment modifications of the tumor's immune profile (LE3).

20 **Before any chemotherapy, it is recommended that ovarian carcinomas (histologic type**
21 **and grade) be diagnosed positively from biopsy samples and not from cytology (grade**
22 **C). A surgical biopsy with multiple samples from different tumor sites is recommended**
23 **before neoadjuvant chemotherapy for women with carcinomatosis of a presumed**
24 **ovarian, tubal, or primary peritoneal origin (Grade C). A needle larger than 16G is**
25 **recommended for image-guided microbiopsies, and at least three biopsy cores should be**

26 **taken (Grade C). If no immunohistochemical study has been performed on the sample**
27 **before chemotherapy or in cases of major morphologic discordance, this examination**
28 **can be performed on residual tumor material after chemotherapy (Grade C).**

29 Preanalytic factors such as cold ischemia time, type of fixative, and the duration of fixing
30 modify morphology as well as the preservation of proteins and nucleic acids. (LP4).

31 **After a biopsy for suspected ovarian, tubal, or primary peritoneal carcinomatosis, the**
32 **tissue samples should be fixed in neutral buffered formalin (with 4% formaldehyde)** as
33 rapidly as possible (<1 h after excision) (for optimal morphologic, immunohistochemical, and
34 nucleic acid preservation) (**grade C**). Vacuum packing and storage at +4°C can be an
35 alternative, but only for very large pieces of excised tissue, to prolong this delay to a
36 maximum of 48 h (grade C). Tissue samples (for biopsies) should be fixed for at least 6 h
37 (grade C).

38 There are no data about the optimal number of surgical specimens to collect for ovarian
39 carcinomatosis. Mucinous tumors are more heterogeneous than the other histologic types,
40 with a mixture of benign, borderline, and invasive carcinoma zones that require more
41 extensive sampling than serous carcinomas (LE3). Some high-grade serous carcinomas of the
42 ovary and peritoneum are in fact of tubal origin, with the presence of high-grade serous tubal
43 intraepithelial carcinoma (STIC) and thus require histologic study of the tubes (LE3).
44 Sampling an omentectomy specimen with no macroscopic lesion by a mean of 3 to 6 blocks
45 (depending on the size of the specimen) enables detection of most of the microscopic damage
46 of the omentum (LE2). Use of the WHO 2014 classification and immunohistochemistry
47 (including the anti-EMA, CK7, CK20, PAX8, WT1, p53, RE, RP, HNF1b and/or napsin A
48 antibodies) helps to improve intra- and inter-observer agreement (LE2) for the diagnosis of
49 histologic subtypes.

50 For pathology examination of excised tissue containing ovarian, tubal, or primary
51 peritoneal carcinomas, preferential sampling is recommended from the solid areas, the
52 tumor capsule, and areas of different macroscopic appearance (Grade C). In view of the
53 heterogeneous nature of mucinous ovarian masses, 1 to 2 tissue blocks should be
54 collected for each cm of tumor (Grade C). To determine the origin of a high-grade
55 serous carcinoma (ovarian versus tubal versus peritoneal), the tube and the entire tubal
56 infundibulum should be sampled (Grade C). When there is no macroscopic involvement
57 of the omentum, 6 tissue blocks should systematically be taken to detect most of the
58 microscopic damage (Grade B). When macroscopic involvement of the omentum is
59 observed, only one block should be taken, from the bulkiest macroscopic tumor nodule
60 (Grade B). For the histologic diagnosis of the histologic subtypes and grade of an
61 ovarian, tubal, or primary peritoneal carcinoma, the WHO 2014 classification should be
62 used (Grade C) and an immunohistochemical study should be performed with a panel of
63 antibodies (selected among the following: EMA, CK7, CK20, PAX8, WT1, p53, RE, RP,
64 HNF1b, and/or napsin A) (Grade B).

65 Women with somatic mutations of the BRCA genes must be referred for an oncogenetic
66 consultation. A study by INCa published in 2017 describes the importance of looking for a
67 constitutional BRCA mutation and its utility in monitoring women and their family members
68 at risk.

69 The size of the most bulky residual site gives the best prognostic correlation for neoadjuvant
70 chemotherapy for ovarian, tubal, or primary peritoneal carcinomatosis (LE3). Most studies
71 show a positive correlation between a complete histologic response (from none to <5% of
72 remaining tumor cells) and survival (LE3). No data show a significant correlation between
73 extent of response and survival (but no studies have used the same score). The Chemotherapy

74 Response Score (CRS) score presents the best interobserver diagnostic reproducibility for
75 response to chemotherapy (LE3), especially for the omentum (LE3).

76 **The pathology report of excised tissue after chemotherapy for ovarian, tubal, and**
77 **primary peritoneal cancers should state the size and the site of the bulkiest residual**
78 **tumor nodule (Grade C). The pathology report should also state if there are no (or <**
79 **5%) residual tumor cells after chemotherapy (Grade C).**

80 The pathology report for ovarian, tubal, or primary peritoneal carcinomatosis should mention
81 the items listed above.

82

Accepted Manuscript

83 The authors' potential relationships of interests are listed at:
84 <https://www.transparence.sante.gouv.fr>.

85

86

87 **Acknowledgments:**

88 The authors want to thank Mme Marianne Duperray and Mme Sophie Morois for their
89 valuable logistic support in the development of these clinical practice guidelines.

90 The authors thank the following professional societies: CNGOF, FRANCOGYN, SFOG,
91 SFAR, GINECO-ARCAGY, SCGP, SFCO, and the RRC; the IMAGIN patient association,
92 and the expert reviewers for their attentive review of these clinical practice guidelines: (list:
93 [https://www.e-cancer.fr/Professionnels-de-sante/Recommandations-et-outils-d-aide-a-la-](https://www.e-cancer.fr/Professionnels-de-sante/Recommandations-et-outils-d-aide-a-la-pratique)
94 [pratique](https://www.e-cancer.fr/Professionnels-de-sante/Recommandations-et-outils-d-aide-a-la-pratique)).

95

96

97 **Références**

- 98 1. Huchon C, Lavoue V, Daraï E. Tumeurs épithéliales de l'ovaire. Méthodes et
99 organisation. Recommandations françaises communes du CNGOF, FRANCOGYN, SFOG,
100 GINECO-ARCAGY et labellisées INCa. Gynécologie, Obstétrique, Fertilité, Sénologie 2018.
- 101 2. Thomassin-Naggara I, Daraï E, Lécuru F, Bellucci A, Fournier L. valeur diagnostique de
102 l'imagerie (échographie, doppler, scanner, IRM, et PET scan) pour le diagnostic ET LE BILAN
103 D'EXTENSION d'un cancer de l'ovaire. Recommandations communes dU FRANCOGYN, du
104 CNGOF, d'ARCAGY-GINECO et de la SFOG, labelisée INCa. . Gynécologie, Obstétrique,
105 Fertilité, Sénologie 2018.
- 106 3. Bendifallah S, Akladios C, Senechal C, Ouldamer L. Pertinence des marqueurs
107 tumoraux, scores (cliniques et biologiques) et algorithmes à visée diagnostique et
108 pronostique devant une masse ovarienne suspecte d'un cancer épithélial: Recommandations
109 de Pratique Clinique communes de FRANCOGYN, CNGOF, SFOG, ARCAGY-GINECO, labélisée
110 par l'INCa. . Gynécologie, Obstétrique, Fertilité, Sénologie 2018.
- 111 4. Devouassoux M, Le Frère-Belda MA, Leary A. Biopathologie des carcinomes ovariens
112 des stades précoces et avancés : Recommandations françaises communes du CNGOF,
113 FRANCOGYN, SFOG, GINECO-ARCAGY et labellisées INCa. Gynécologie, Obstétrique, Fertilité,
114 Sénologie 2018.
- 115 5. Bolze PA, Bourgin C, Collinet P, Golfier F. Chirurgie des stades précoces des cancers
116 ovariens. Recommandations françaises communes du CNGOF, FRANCOGYN, SFOG, GINECO-
117 ARCAGY et labellisées INCa. Gynécologie, Obstétrique, Fertilité, Sénologie 2018.
- 118 6. Ferron G, Narducci F, Pouget N, Touboul C. Chirurgie des cancers avancés de l'ovaire.
119 Recommandations de Pratique Clinique communes de FRANCOGYN, CNGOF, SFOG et
120 ARCAGY-GINECO, labélisées par l'INCa. Gynécologie, Obstétrique, Fertilité, Sénologie 2018.
- 121 7. Alfonsi P, Bonnet F, Lambaudie E, Leblanc E, Lemoine A. Soins péri-opératoires dans
122 le cancer de l'ovaire. Recommandations Françaises communes dU FRANCOGYN, du CNGOF,
123 d'ARCAGY-GINECO et de la SFOG, labelisée INCa. Gynécologie, Obstétrique, Fertilité,
124 Sénologie 2018.
- 125
- 126

QFigure 1: Management of presumed early-stage ovarian cancer

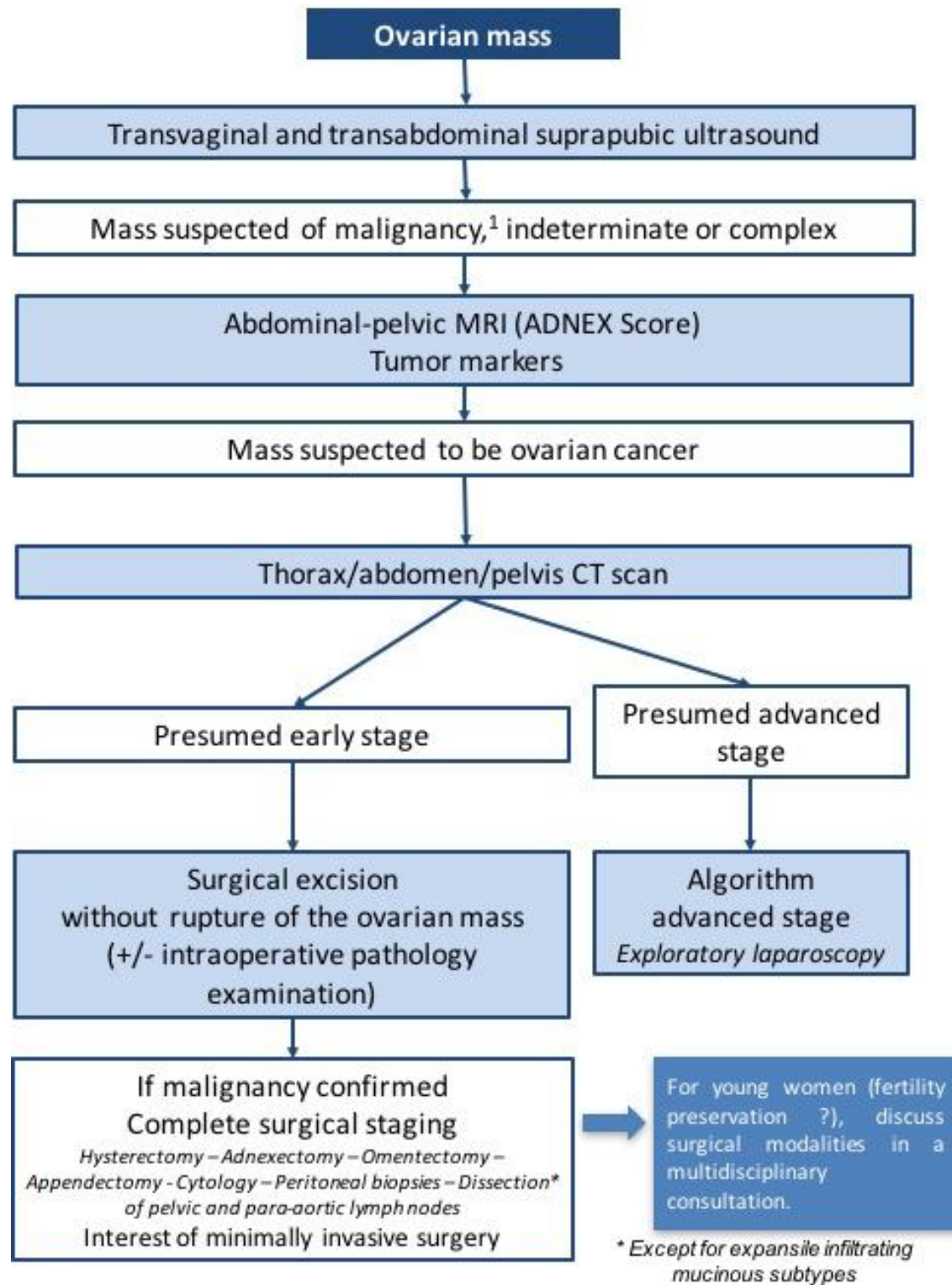


Figure 2: Management of a FIGO stage III ovarian, tubal, or primary peritoneal cancer

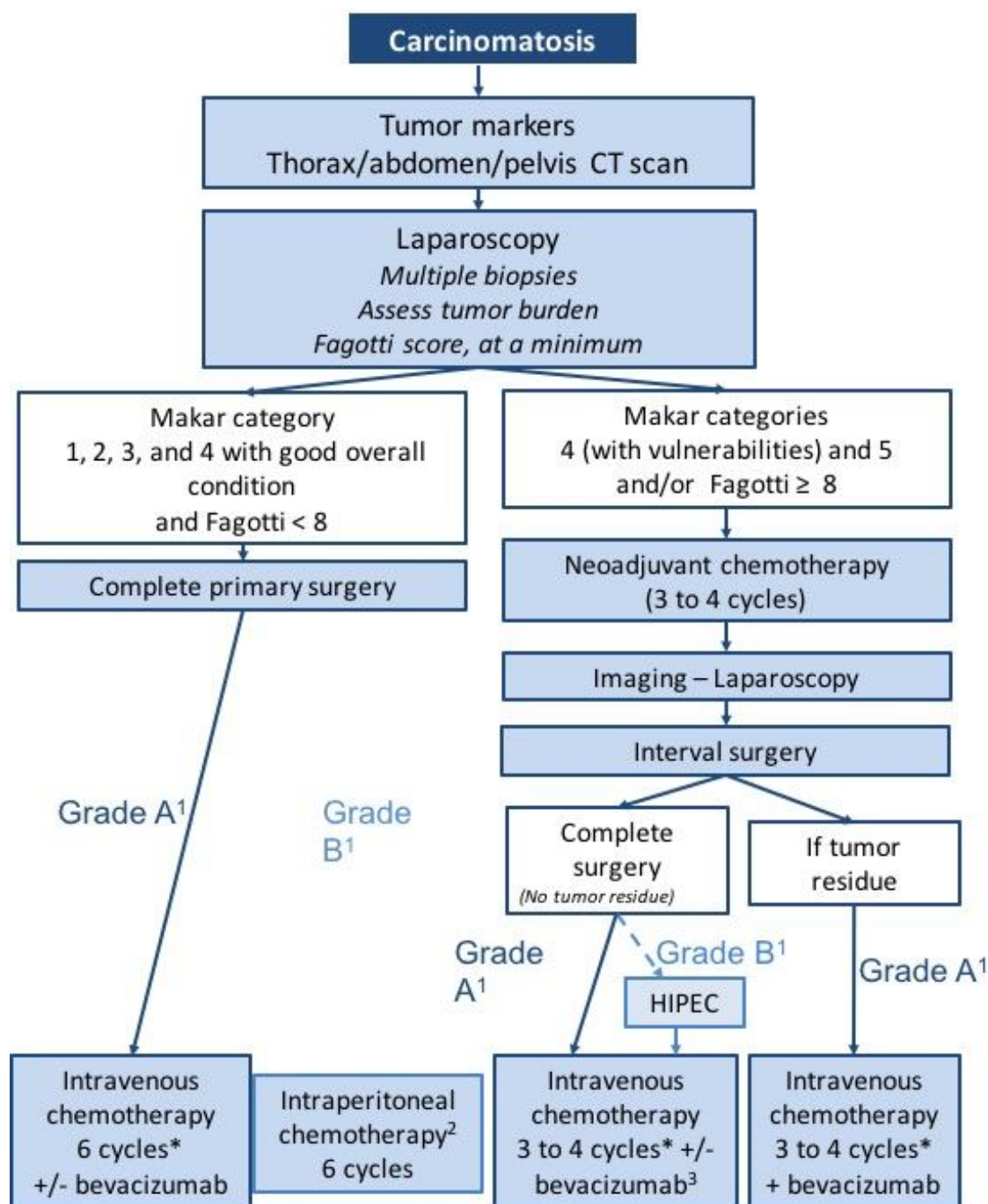
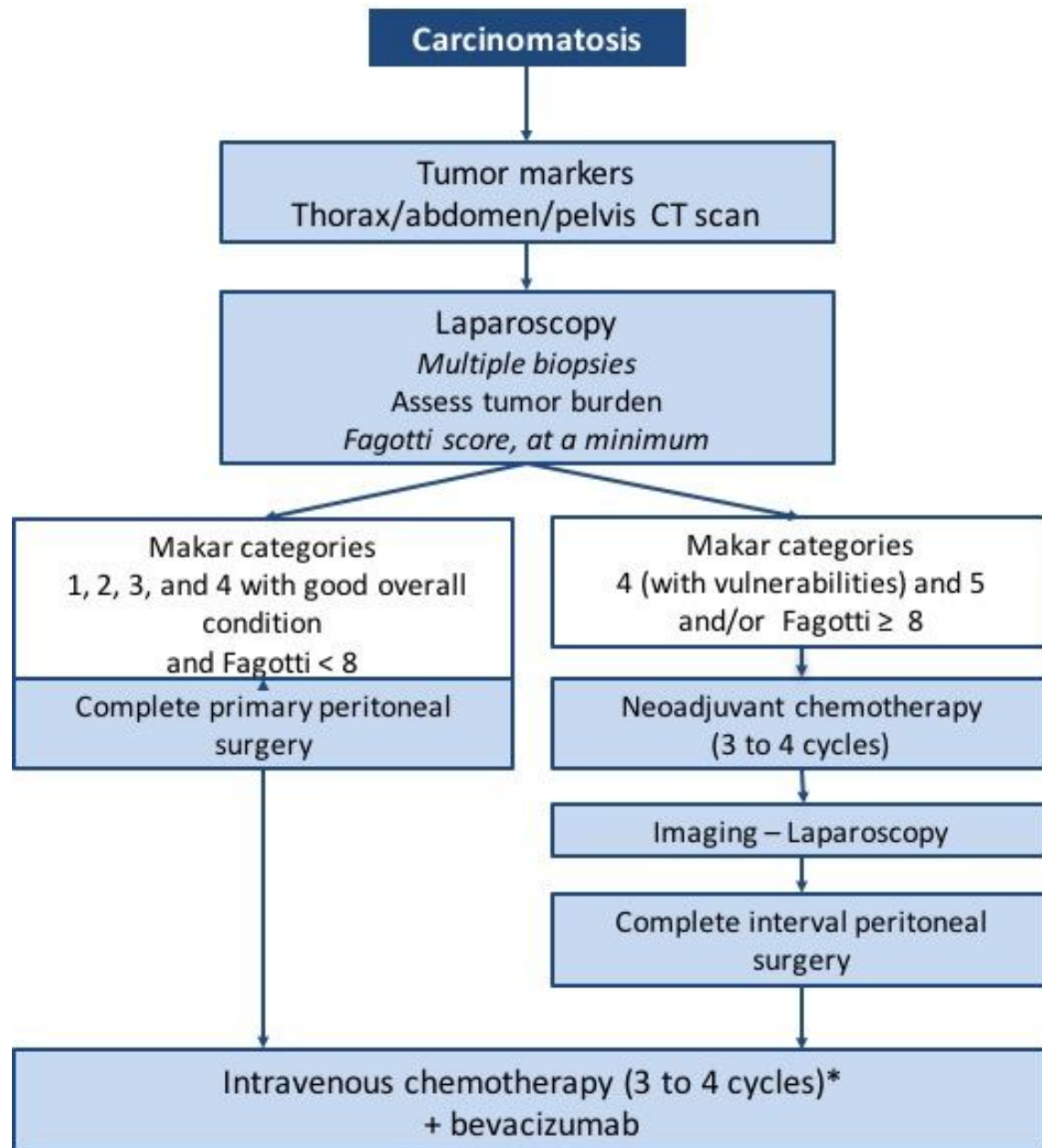


Figure 3: Management of a FIGO stage IV ovarian, tubal, or primary peritoneal cancer



Makar categories	
Category 1	Tumor located in pelvis Little or no ascites No need for gastrointestinal resection
Category 2	Tumor located in pelvis Little or no ascites Gastrointestinal resection is envisioned
Category 3	A large portion of the tumor is localized in the supramesocolic space Little or no ascites No need for gastrointestinal resection
Category 4	A large portion of the tumor is localized in the supramesocolic space Little or no ascites Gastrointestinal resection is envisioned
Category 5	A large portion of the tumor is localized in the supramesocolic space Abundant ascites or miliairy patterns on the mesentery. Need for several gastrointestinal resections

Table 1: The 10 simple ultrasound rules for an adnexal mass

Rules for predicting a benign tumor		Rules for predicting a malignant tumor	
B1	Unilocular	M1	Irregular solid mass
B2	The largest diameter of the largest solid component < 7 mm	M2	Ascites
B3	Acoustic shadow	M3	≥ 4 papillary structures
B4	Smooth multilocular tumor with largest diameter < 100 mm	M4	Irregular multilocular tumor with maximum diameter ≥ 100 mm
B5	No blood flow	M5	Intense vascularization on Doppler

Accepted Manuscript

Table 2: ADNEX MR score to characterize the risk of malignancy of adnexal masses on MRI

	Risk of malignancy	Classification
No mass visible on MRI	0%	Very low risk
T2-weighted high signal intensity (type 5) unilocular cyst or tube without solid tissue	0-1.7%	low risk
Unilocular endometriotic cyst with no wall enhancement		
Purely fatty mass, without solid tissue		
No wall enhancement		
Low T2-weighted and low b (1000 sec/mm ²) -weighted signal intensity within solid tissue		
T1-weighted high signal intensity unilocular cyst (type 3-4) (not fatty or endometriotic)	5.1-7.7%	Intermediate risk
Multilocular cyst without solid tissue		
Type 1 time-signal intensity curve within solid tissue;		
Type 2 time-signal intensity curve within solid tissue	26.6-57.1%	Elevated risk
Type 3 time-signal intensity curve within solid tissue	68.3-100%	Very high risk
Peritoneal implants		

Table 3: Fagotti score

Parameters	Score
Omental cake (massive infiltration of the greater omentum)	2: diffuse stomach infiltration 0: isolated sites
Peritoneal carcinomatosis	2: massive NONRESECTABLE peritoneal carcinomatosis or miliary pattern of distribution 0: limited-area carcinomatosis (paracolic gutter or pelvic peritoneum, surgically resectable by peritonectomy)
Diaphragmatic carcinomatosis	2: widespread infiltration or confluent nodules infiltrating most of the diaphragm surface 0: all other cases
Mesenteric retraction	2 mesenteric retraction 0: Absence of mesenteric retraction
Bowel infiltration	2: gastrointestinal resection is envisioned 0: all other cases
Stomach infiltration	2: nodules infiltrating the stomach and/or spleen and/or lesser omentum 0: all other cases
Hepatic metastases	2: any tumor with an area >2 cm 0: all other cases

Table 4: Summary of survival according to tumor residue and primary or interval surgery in advanced ovarian, tubal, and primary peritoneal cancers.

STAGE III - IV	Primary surgery	Interval surgery	Primary surgery	Interval surgery
	Recurrence-free survival (months)		Overall survival (months)	
No residue	20.1-33	16.4	64.1-71.9	66.6
Residue < 1 cm	13-16.8	9.8	28.7-42.4	39.7
Residue > 1 cm	12.9-14.1	7.4	30.7-35	28.4